

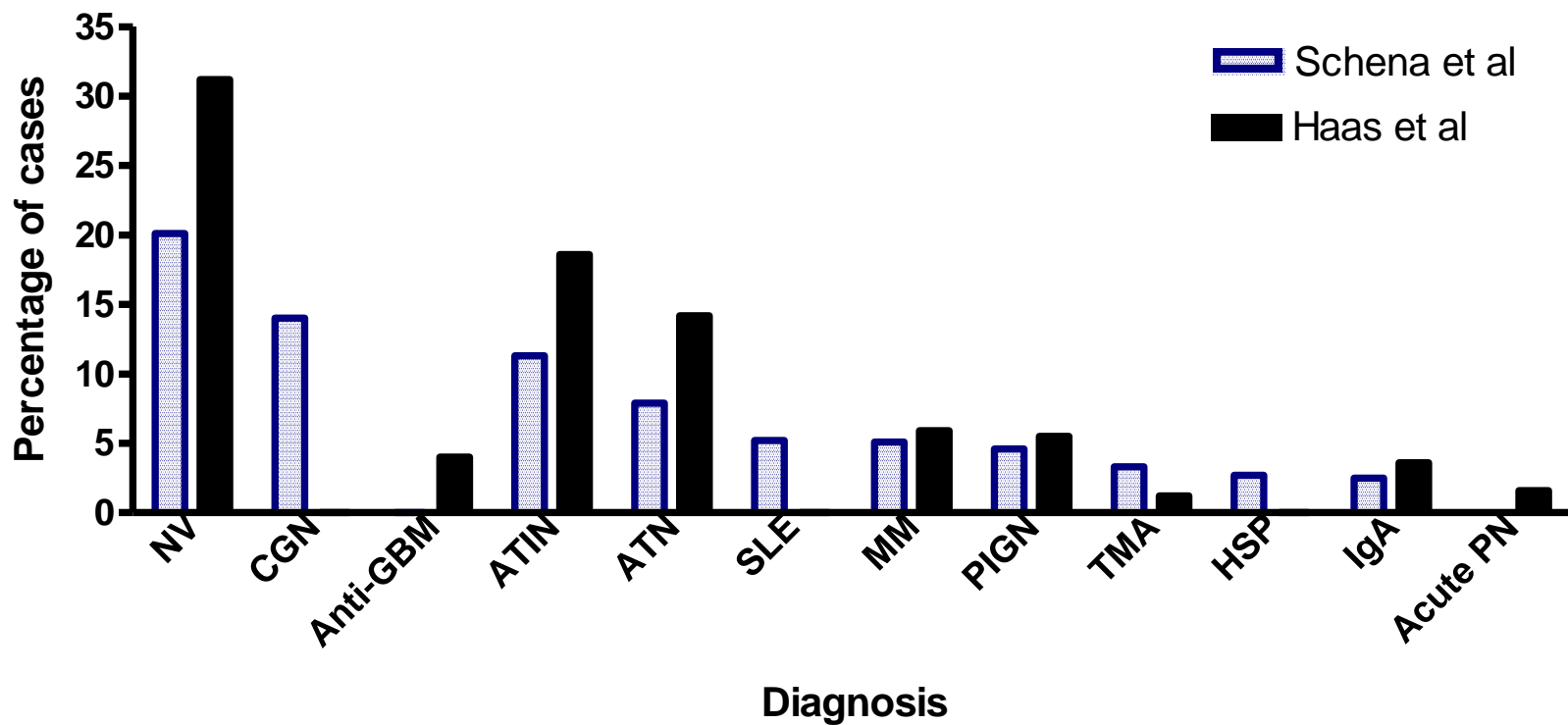
Rapidly progressive glomerulonephritis and how to diagnose it

Alan Salama

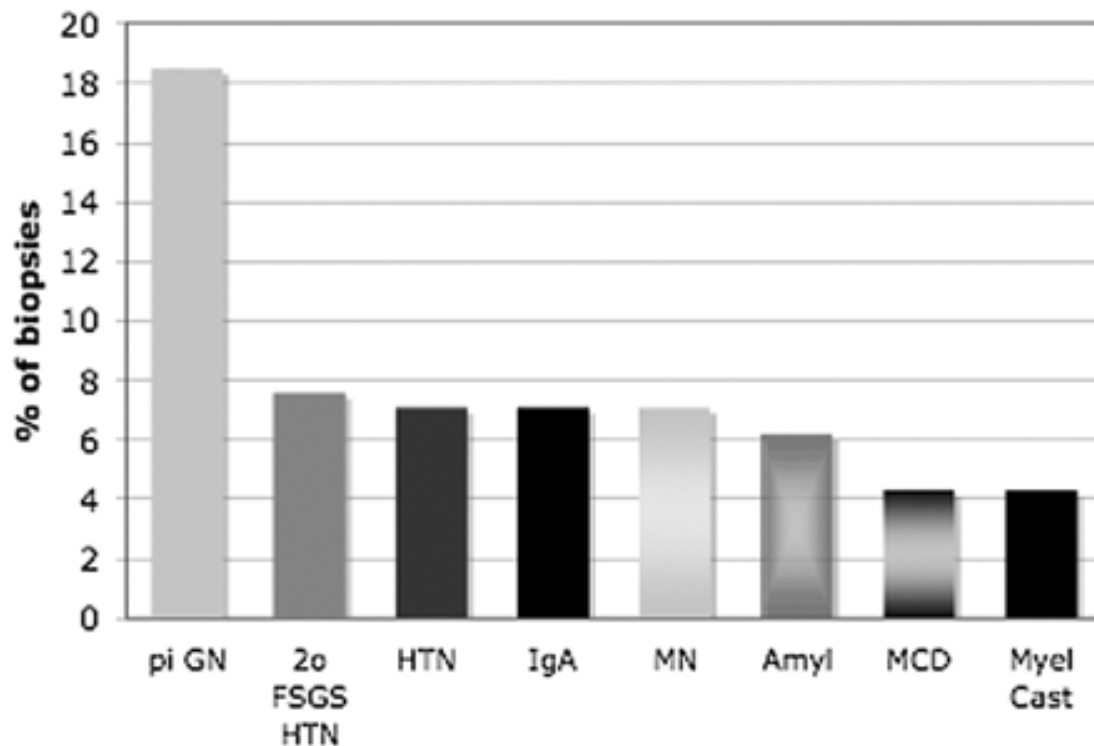
UCL Centre for Nephrology

Royal Free Hospital

Kidney biopsy findings in patients with acute kidney injury not thought to have ATN



Kidney biopsy findings in 235 elderly patients >80 years old



Case

- 79 year old woman
- IHD and dilated cardiomyopathy
- Poor LV function (EF 20%)
- ICD for ventricular tachyarrhythmia

- Admitted under medical team with breathlessness and hypotension
- Treated for pulmonary oedema
- Negative cardiac investigations including normal troponin and no evidence of arrhythmias
- Creatinine 97 Hb 14.8 CRP 32

Case

Macroscopic haematuria

MSU: E.coli (fully sensitive)

Treated with trimethoprim

Cr 131 CRP 42 Hb 13.6

Discharged home

Readmitted 5 days later

Unwell, breathless ?sepsis

Cr 425 Hb 11.5 CRP 92

Antibiotics- ertapenim, diuretics

- What do you as medical registrar/consultant do next?
- What is likely diagnosis?

- What do you as medical registrar/consultant do next?
- What is likely diagnosis?
- Would you biopsy her?

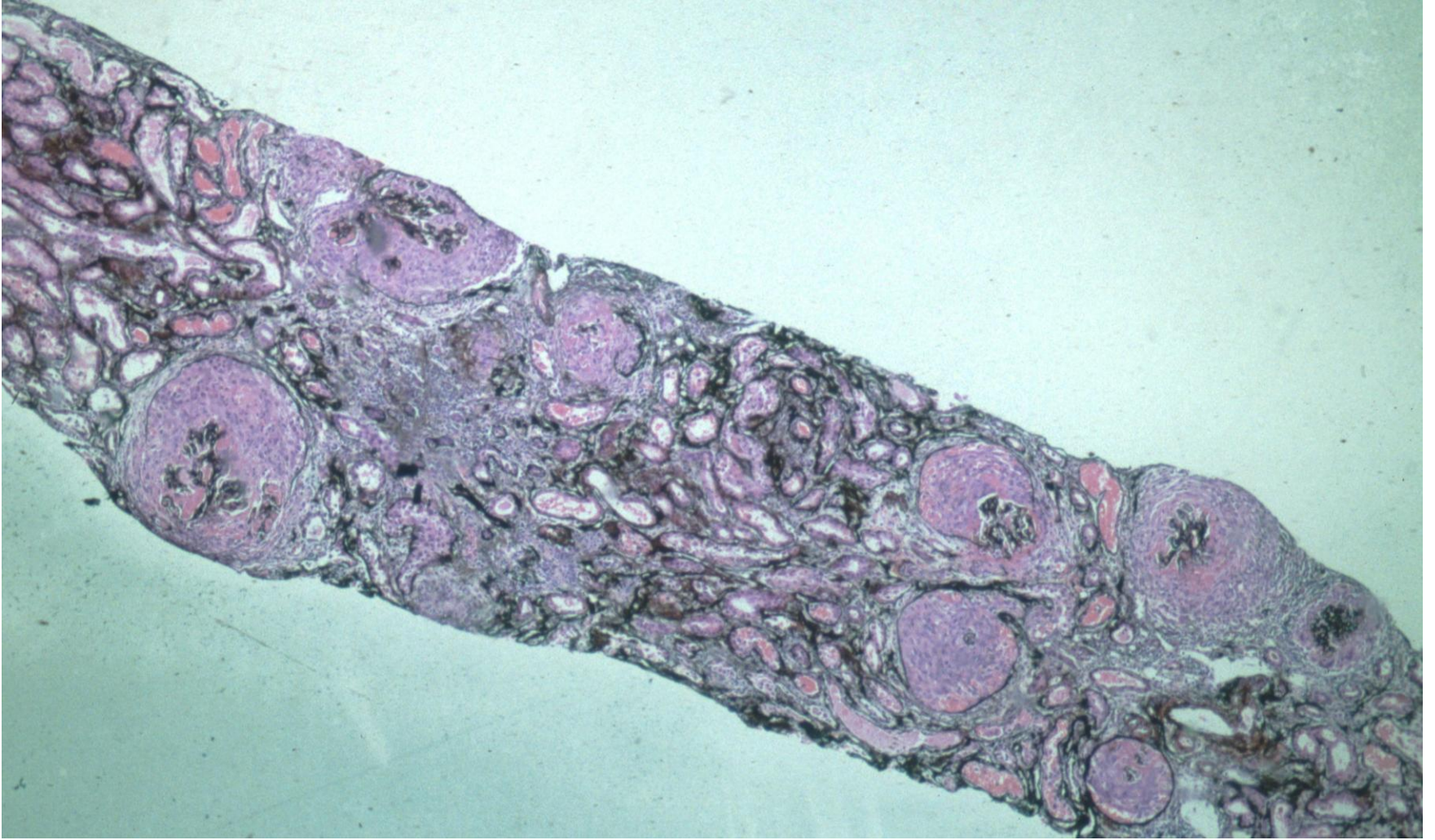
Case

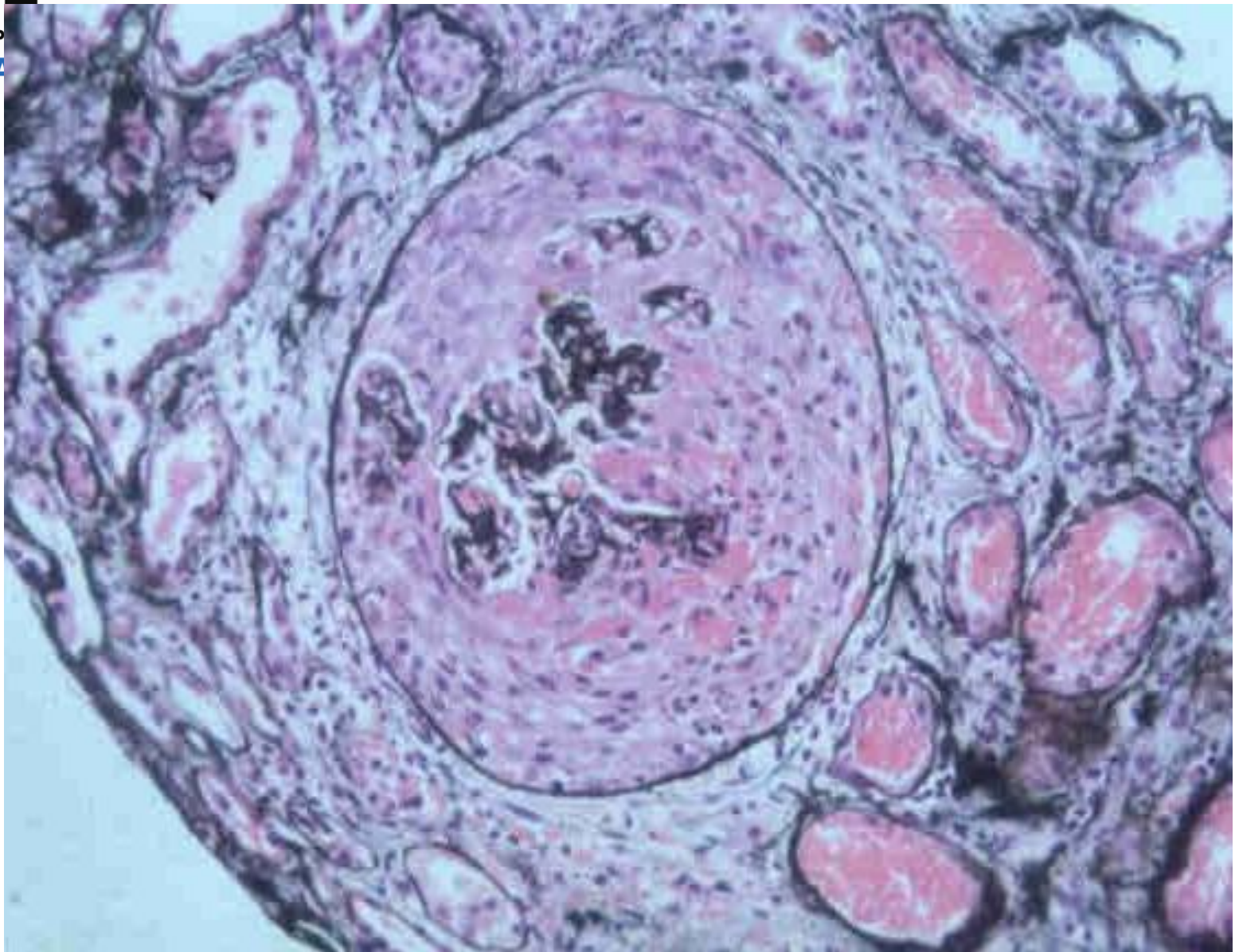
- Referred to renal team
- Cr 519 Ur 36 Alb 31 Ca 1.8 PO4 2.0 CRP 131
- Hb 10.1 WCC 13.8
- anuric
- Started intermittent dialysis
- Acute screen sent
- ? Sepsis/ATN

Case

HCV, HbSAg, HIV all negative

ANCA negative, C3/C4 normal





Case

HCV, HbSAg, HIV all negative

ANCA negative, C3/C4 normal

Proceeded to biopsy:

7 glomeruli, all with crescents, mild interstitial infiltrate

Linear IgG deposition

No chronic damage

Case

HCV, HbSAg, HIV all negative

ANCA negative, C3/C4 normal

Proceeded to biopsy:

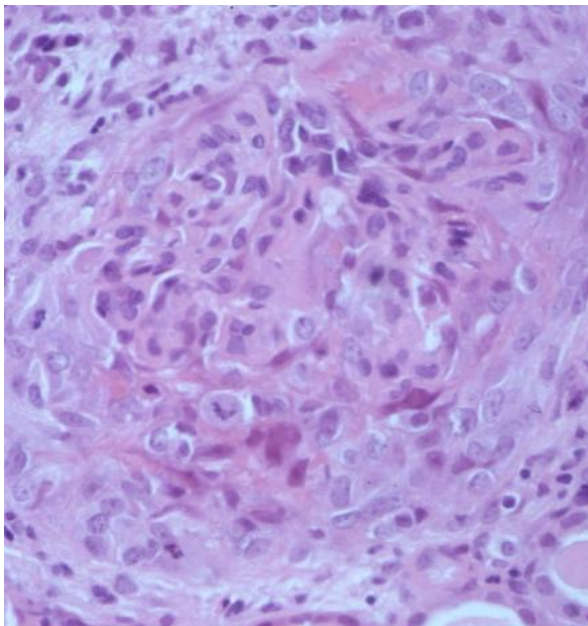
7 glomeruli, all with crescents, mild interstitial infiltrate

Linear IgG deposition

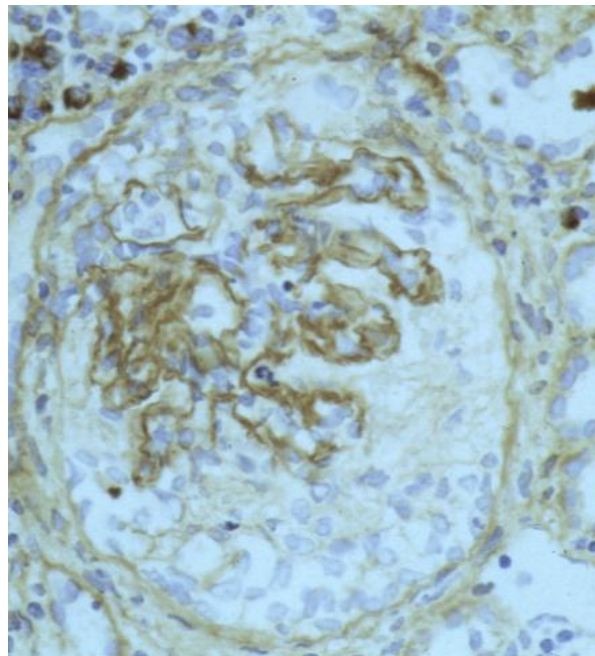
No chronic damage

Anti-GBM Ab >900 IU/ml

H and E



IgG



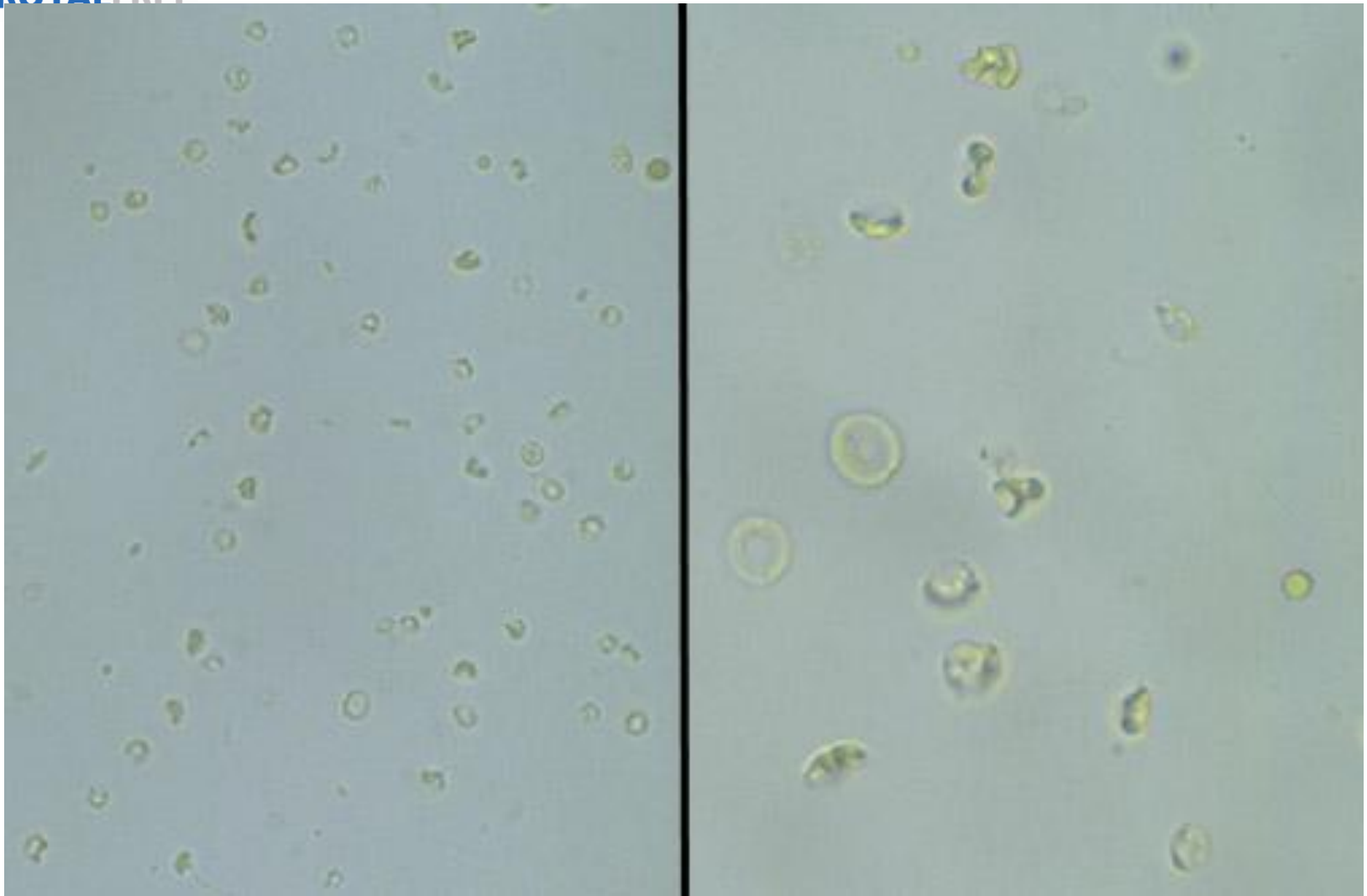
Diagnosis: Crescentic glomerulonephritis due to Anti-GBM disease

Following discussion with patient and family-
Plasmapheresis and Pred/CYC

Stopped after 4 weeks when no renal recovery found

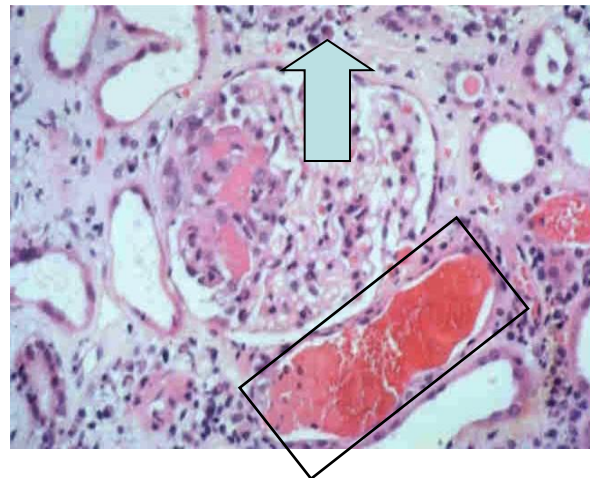
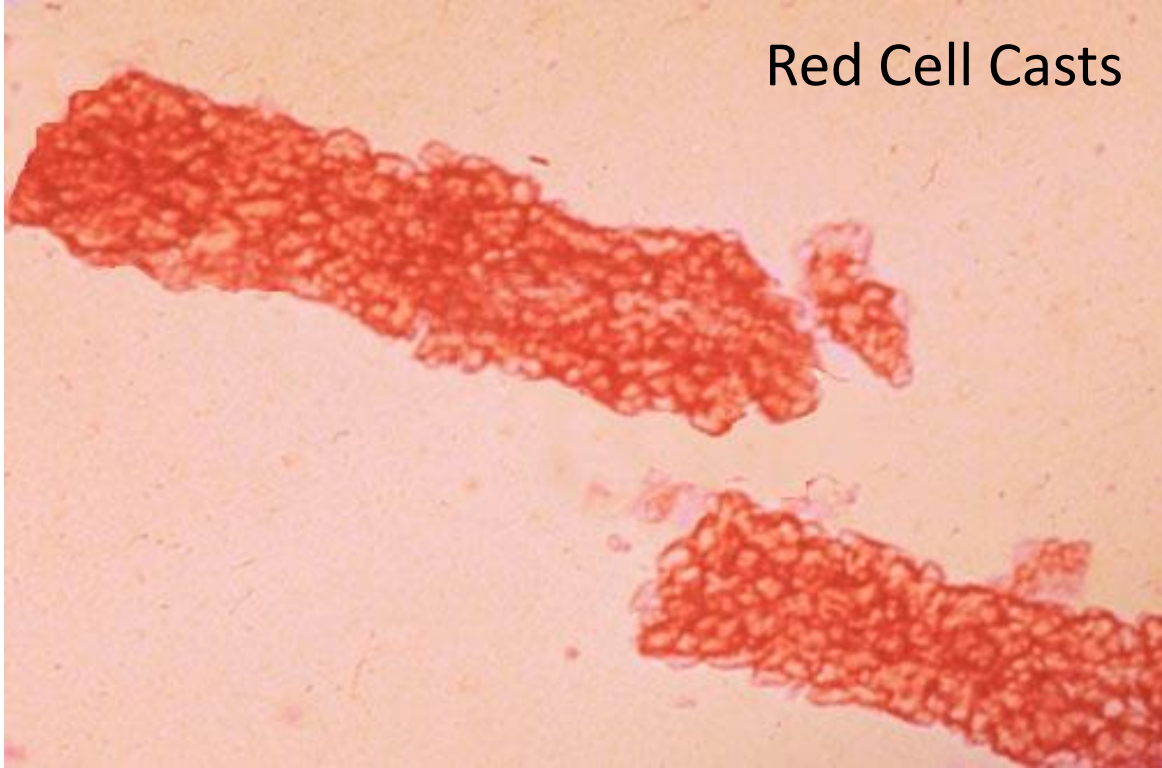
Rapidly Progressive Glomerulonephritis

- Clinical definition of rapid deterioration in renal function (doubling of SCr or halving of GFR within 3 months), due to crescentic glomerulonephritis
- Crescentic glomerulonephritis – may be used for glomerulonephritis with any crescents but WHO suggests >50%
- Critical to make this diagnosis as time = nephrons!
- Think of it if renal function deteriorating and no obvious reason for ATN
- Dipstick and microscope urine



Dysmorphic red cells

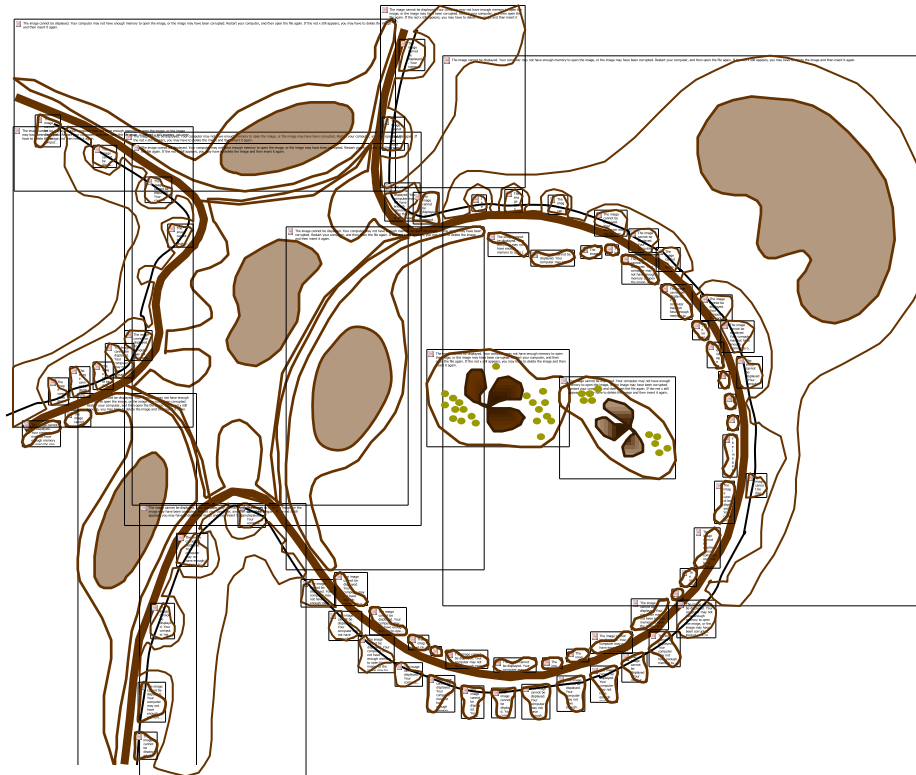Red Cell Casts



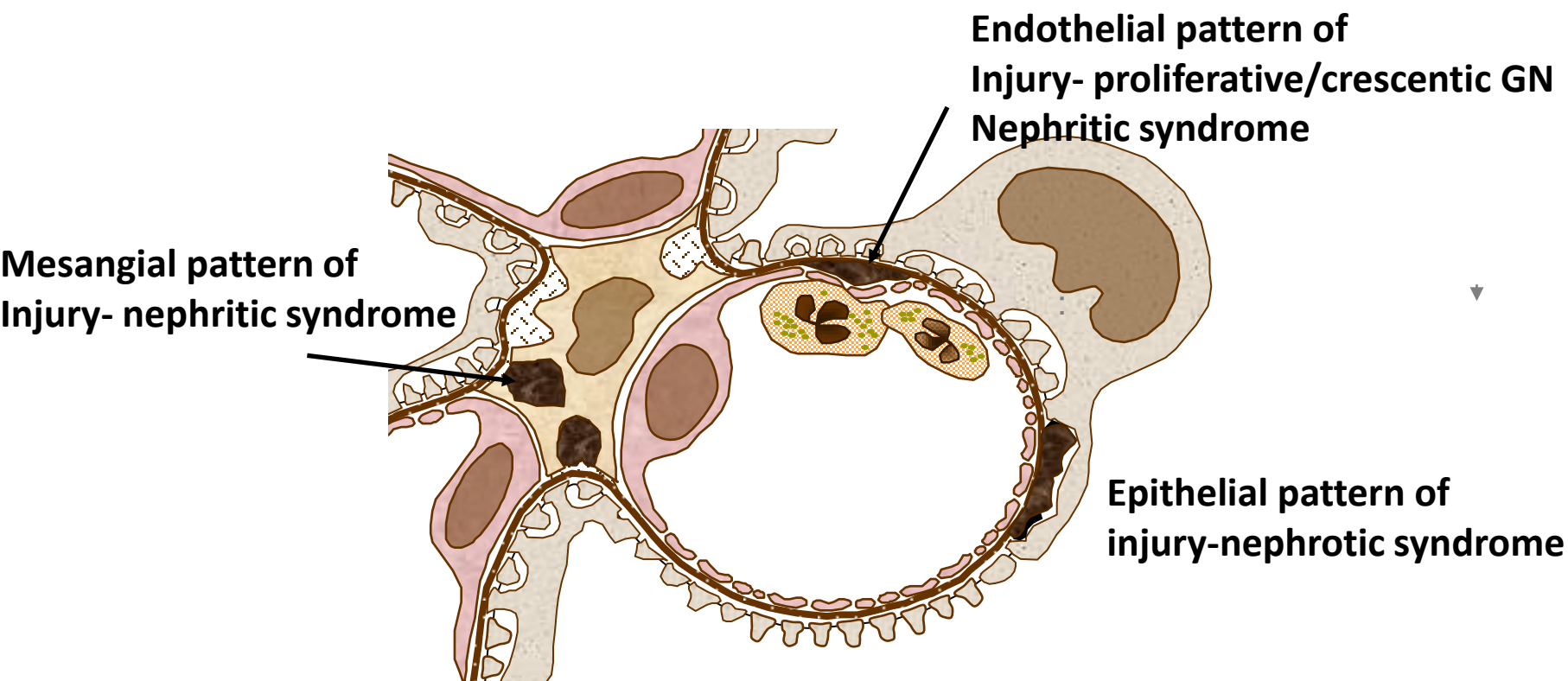
Crescentic glomerulonephritis

- Crescents are an indication of severity of glomerulonephritis rather than its cause
- Complete pathological diagnosis requires analysis of immunofluorescence, electron microscopy and serology

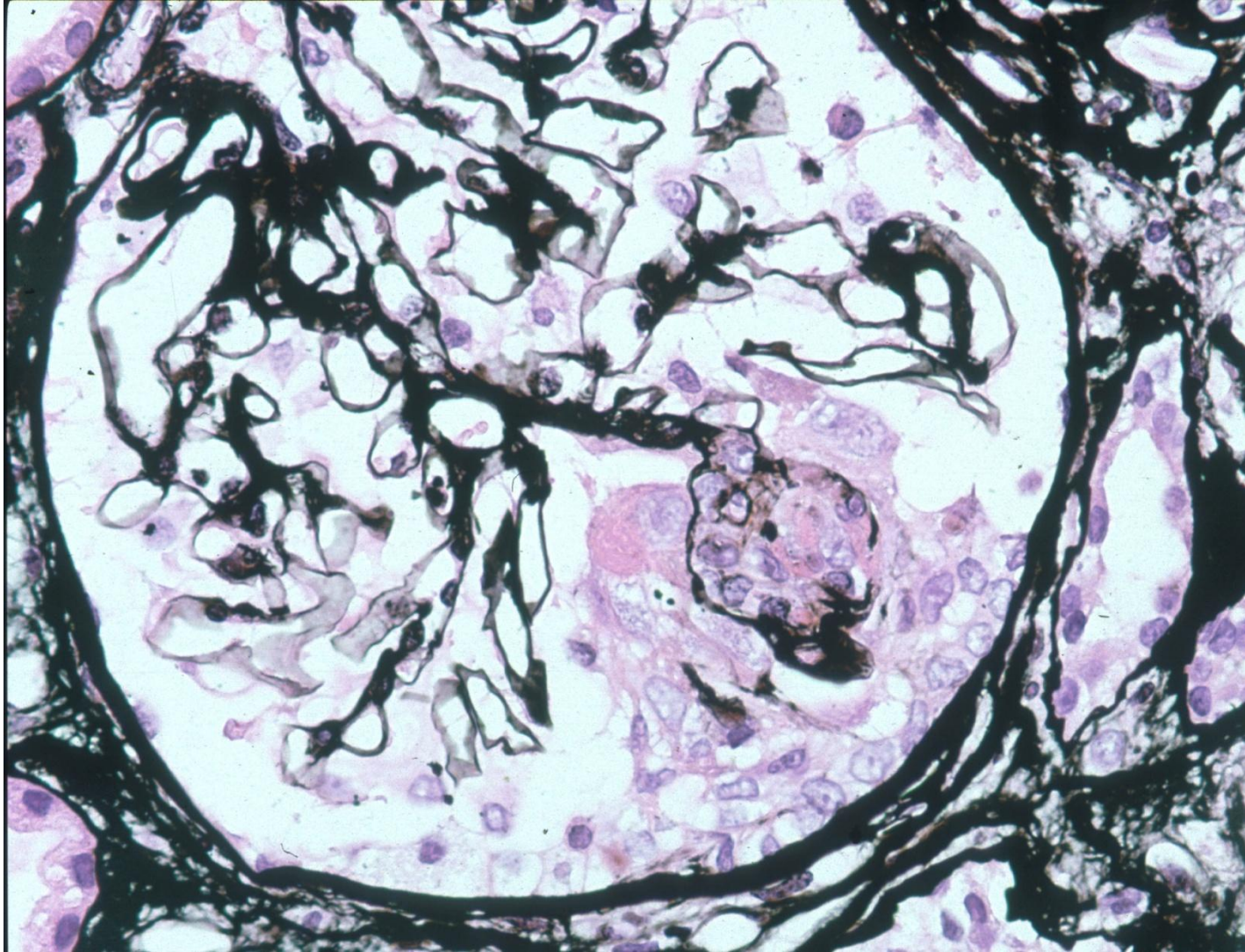
Glomerulus has leukocytes trafficking through it



Crescent formation in immune complex GN correlates with extent of subendothelial IC deposition



Early crescent and GBM rupture



“Holes” in basement membrane

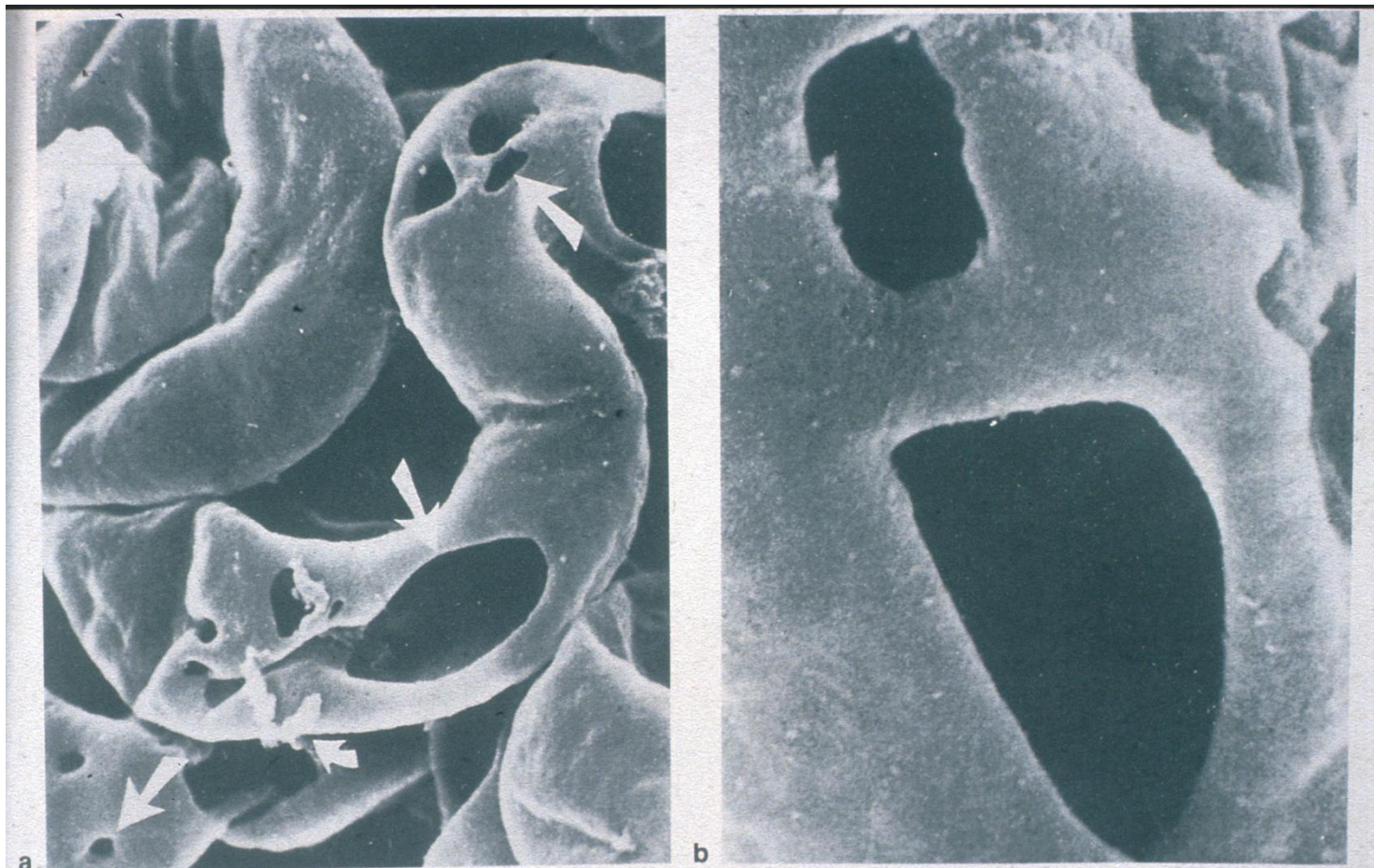


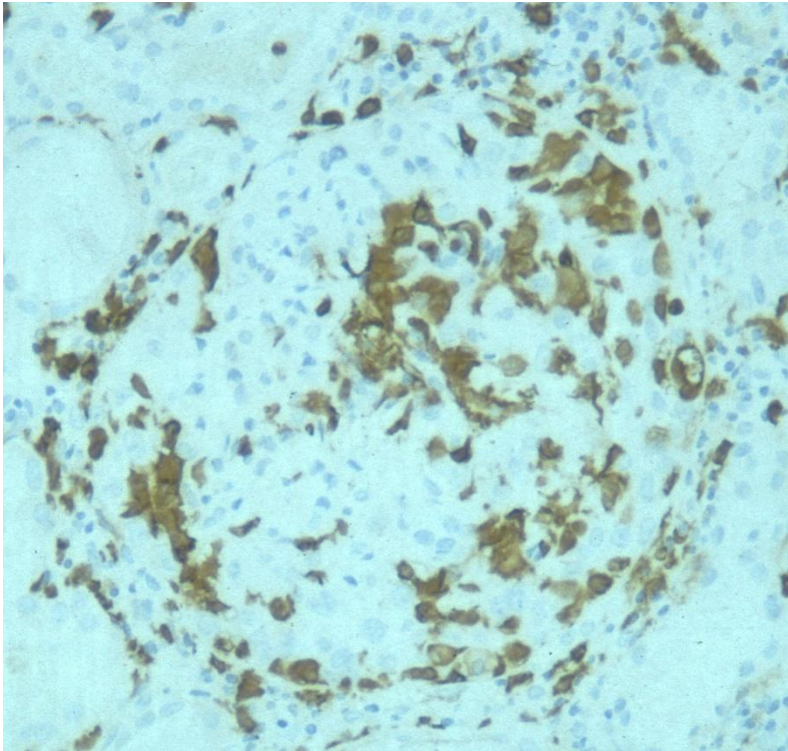
Fig. 7.10 Diffuse crescentic glomerulonephritis. (a) Scanning electron micrograph of a glomerular capillary loop after digestion of the cells leaving only the basement membrane. There are multiple perforations (arrows) of variable sizes in the membrane. The curved arrow indicates residual tissue debris. (b) Two perforations in a glomerular capillary. The sharply demarcated edges curl slightly into the capillary lumen.

(a) $\times 2000$; (b) $\times 6000$

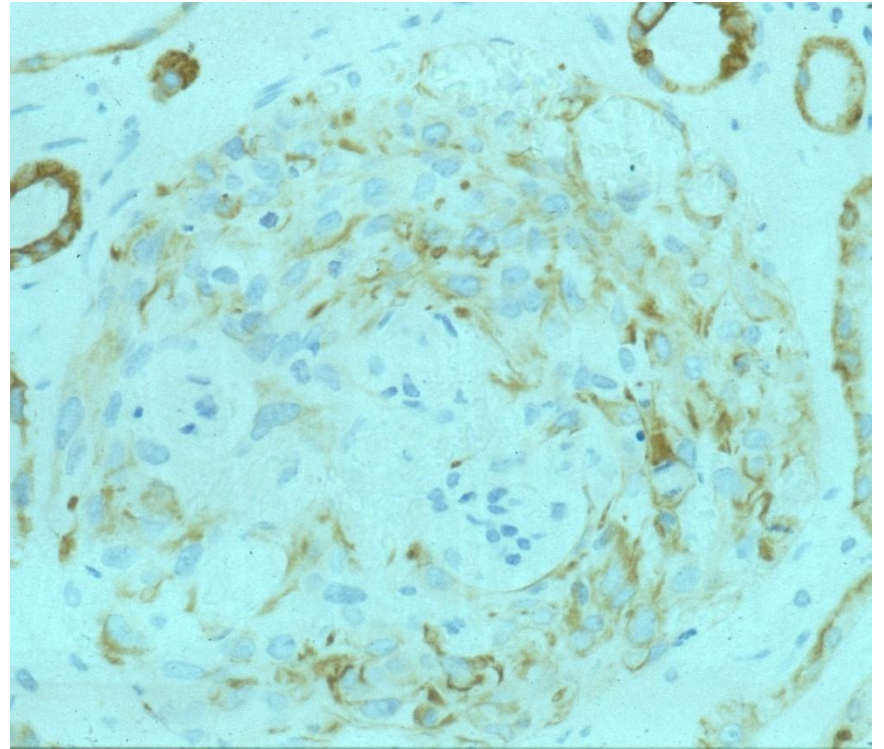
Reproduced by permission from: Bonsib SM. Am J Pathol 1985; 119: 357 (Figs 2B, C)

Generation of crescents

- Breach in GBM leads to accumulation of red cells, leukocytes, fibrin and proteinaceous material in Bowman's space
- Crescents are made up of leukocytes (predominantly macrophages) and proliferating parietal epithelial cells.
- Constituents of crescents will vary depending on age of lesion and initial insult.



Macrophages

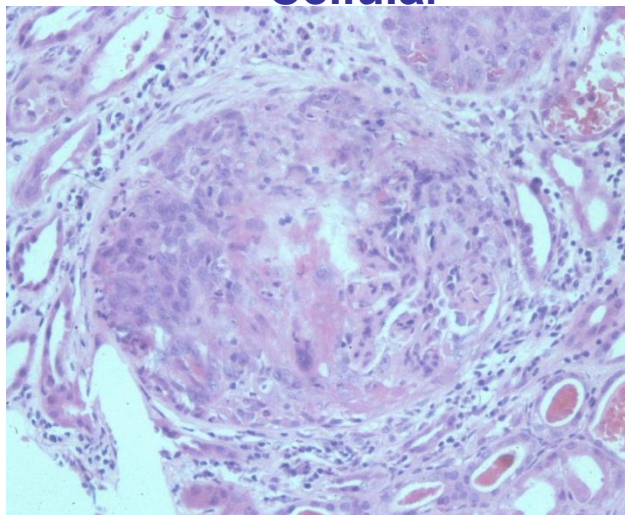


Epithelial cells

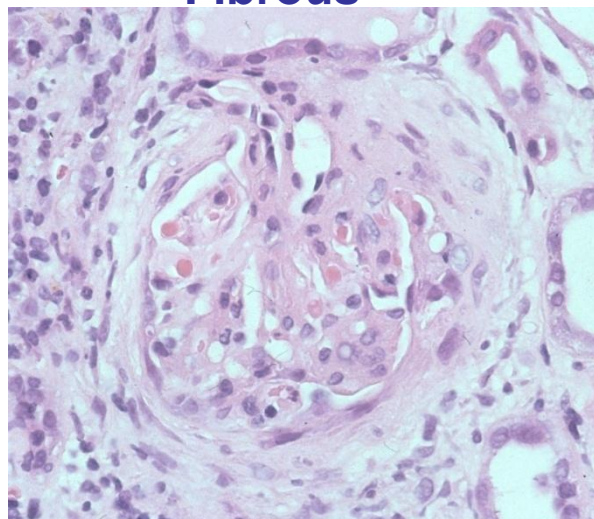
Crescent resolution

- Cells removed through apoptosis or generate scars through deposition of collagen by epithelial cells and fibroblasts (fibrous or fibrocellular crescents)

Cellular



Fibrous



Summary of Crescent formation

Breach in integrity of GBM — ROS, proteases etc from inflammatory cells

Cells and fibrin in Bowman's space

Accumulation of macrophages and proliferating epithelial cells

Apoptosis of cells and laying down of collagen
Fibrocellular crescents and fibrous crescents

Classification of RPGN based on IF findings on renal biopsy

Linear deposits

anti-GBM disease

Granular deposits

1° or 2° immune
complex GN

No (or few) deposits

ANCA-associated GN

Frequency of types of crescentic GN

	Age (years)			
	10-19	20-39	40-64	>65
Anti-GBM	15%	24%	2%	11%
Immune complex	50%	48%	30%	8%
Pauci-immune	35%	28%	69%	82%

Jennette, Heptinstall's Pathology of the Kidney 1998

Crescent formation in different glomerular diseases

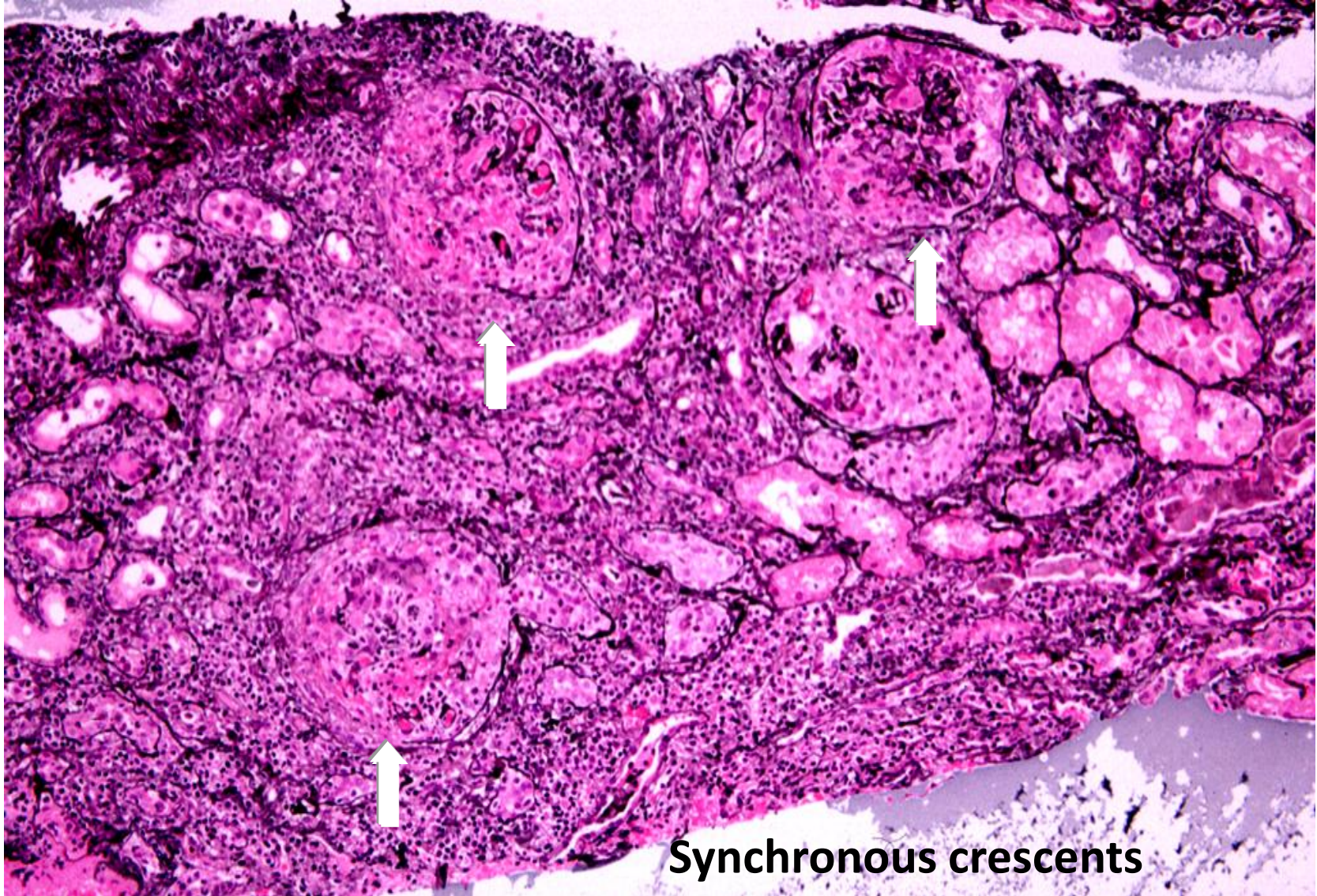Frequency	Patients with any crescents	Patients with >50% crescents
Anti-GBM disease	95	81
Pauci-immune (ANCA-associated)	90	48
Lupus GN (class III and IV)	40	11
Henoch-Schonlein purpura	53	5
IgA nephropathy	27	5
Postinfectious GN	25	3
Fibrillary GN	20	7
Type I membranoproliferative GN	20	3

Jennette, Heptinstall's Pathology of the Kidney 1998

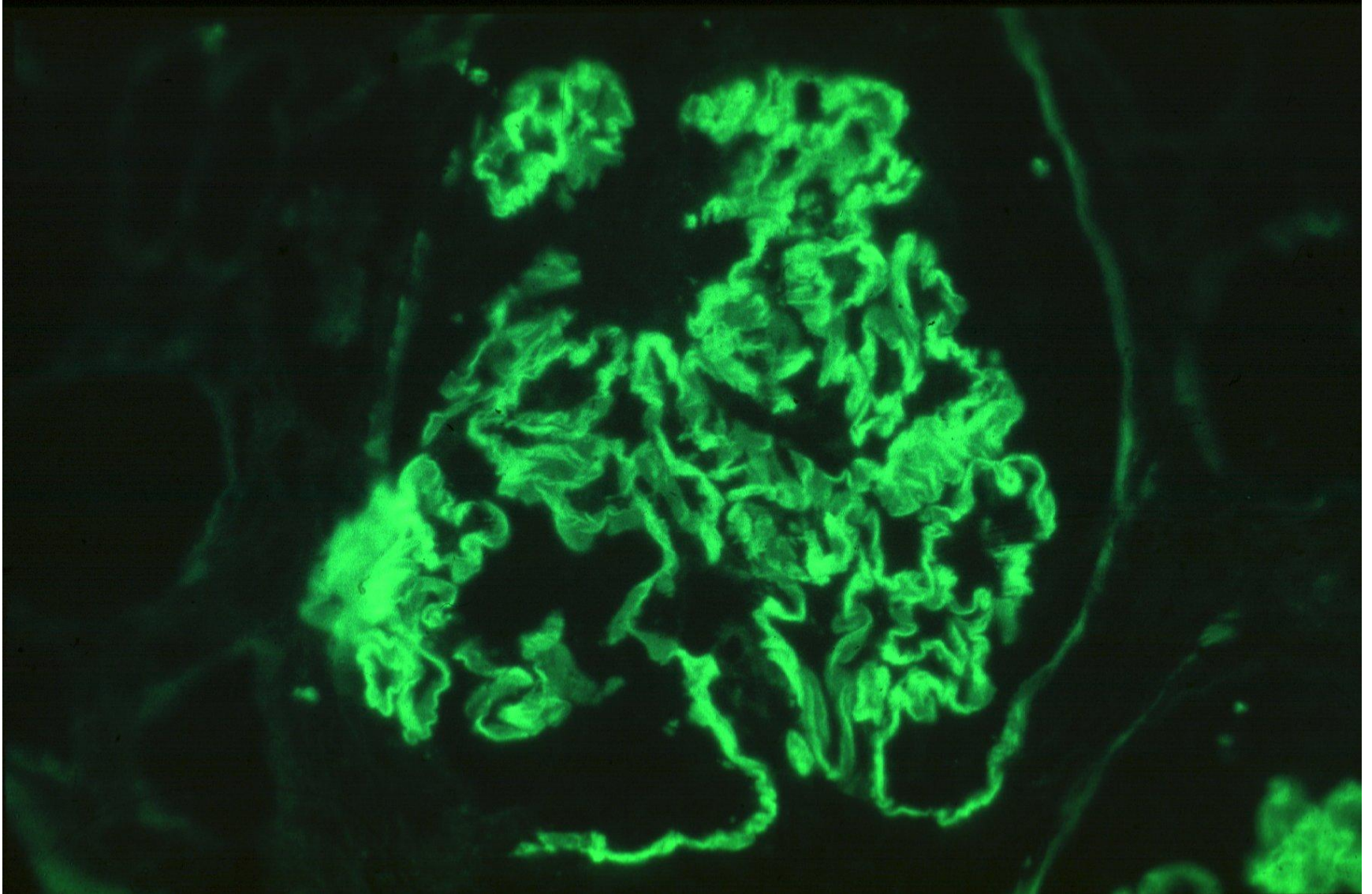
Goodpasture's disease

- Pulmonary-renal syndrome
- 2 peaks of incidence age 20-30, 60-70
- Slight male predominance
- Incidence 0.5-1 case/million/year
- Paucity of prodromal symptoms (unlike AAV)
- 20% cases present with anuria

Goodpasture's disease



Linear Ig deposition on GBM



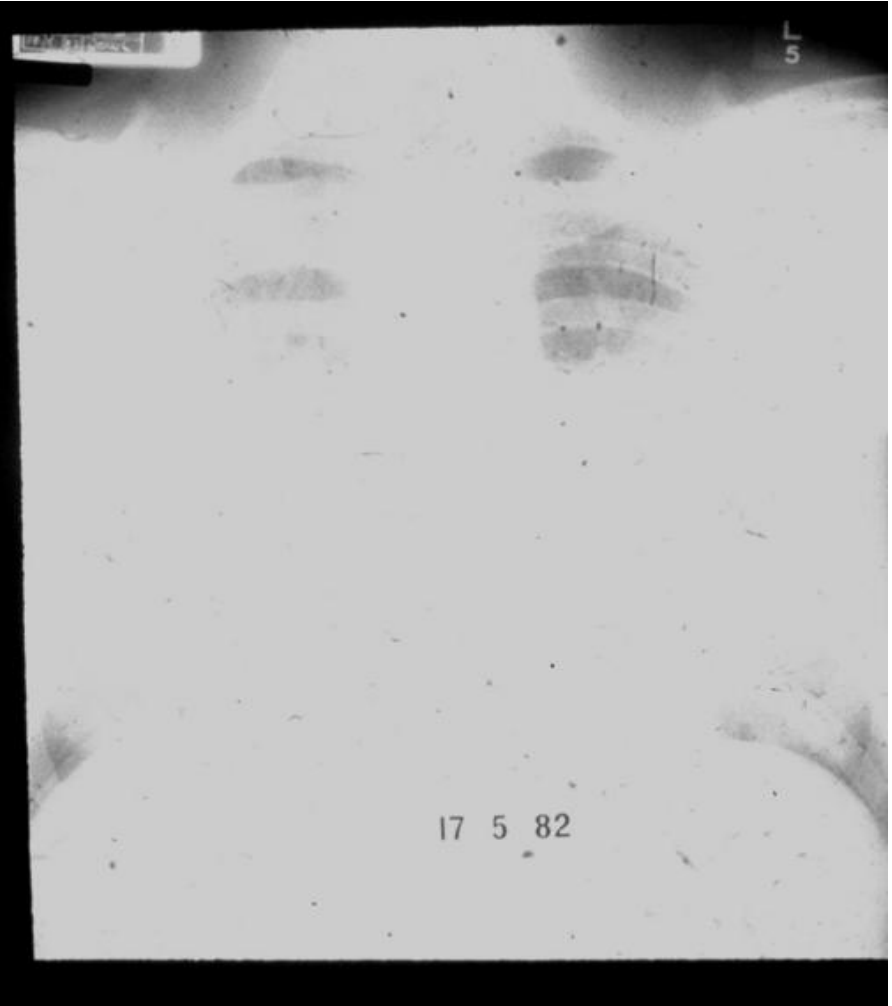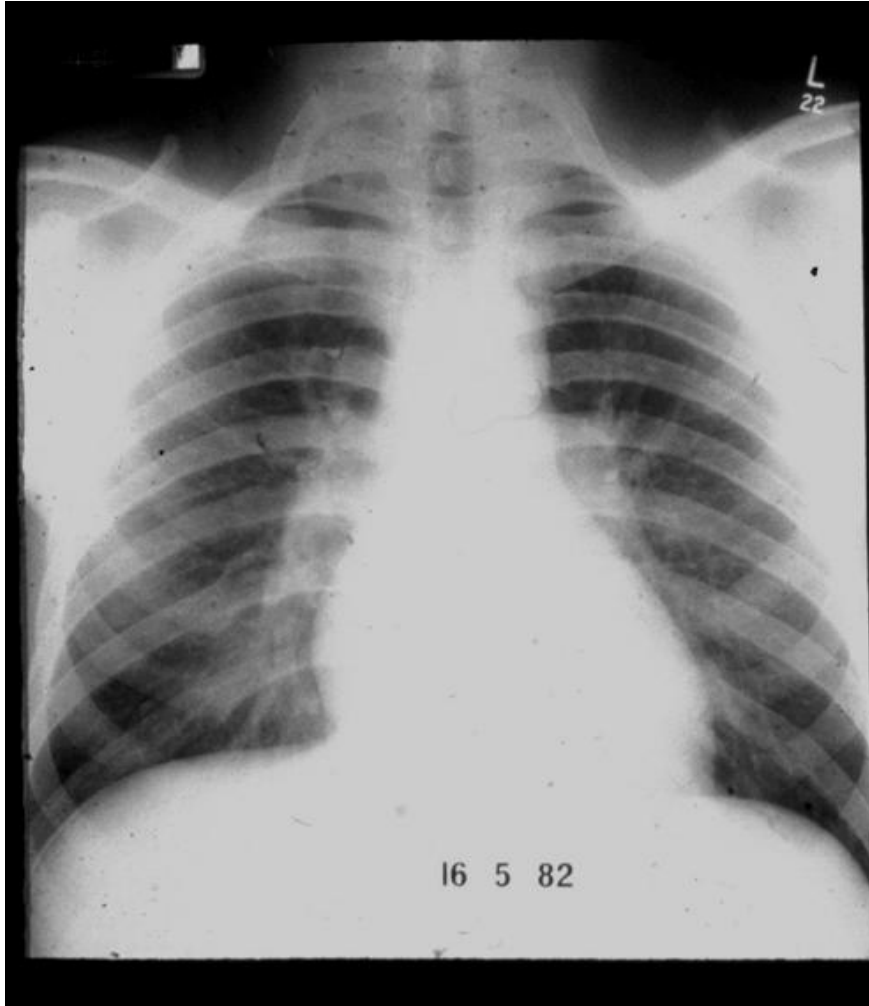
Outcome of treated anti-GBM disease

- 71 patients, median age 40 (17-76), 40 male
- Diagnosis made by assay for anti-GBM antibodies and direct IF on renal biopsy
- 55% on dialysis, 18% creat >500
- Lung haemorrhage in 62%
- All treated with pred/cyclo/PE

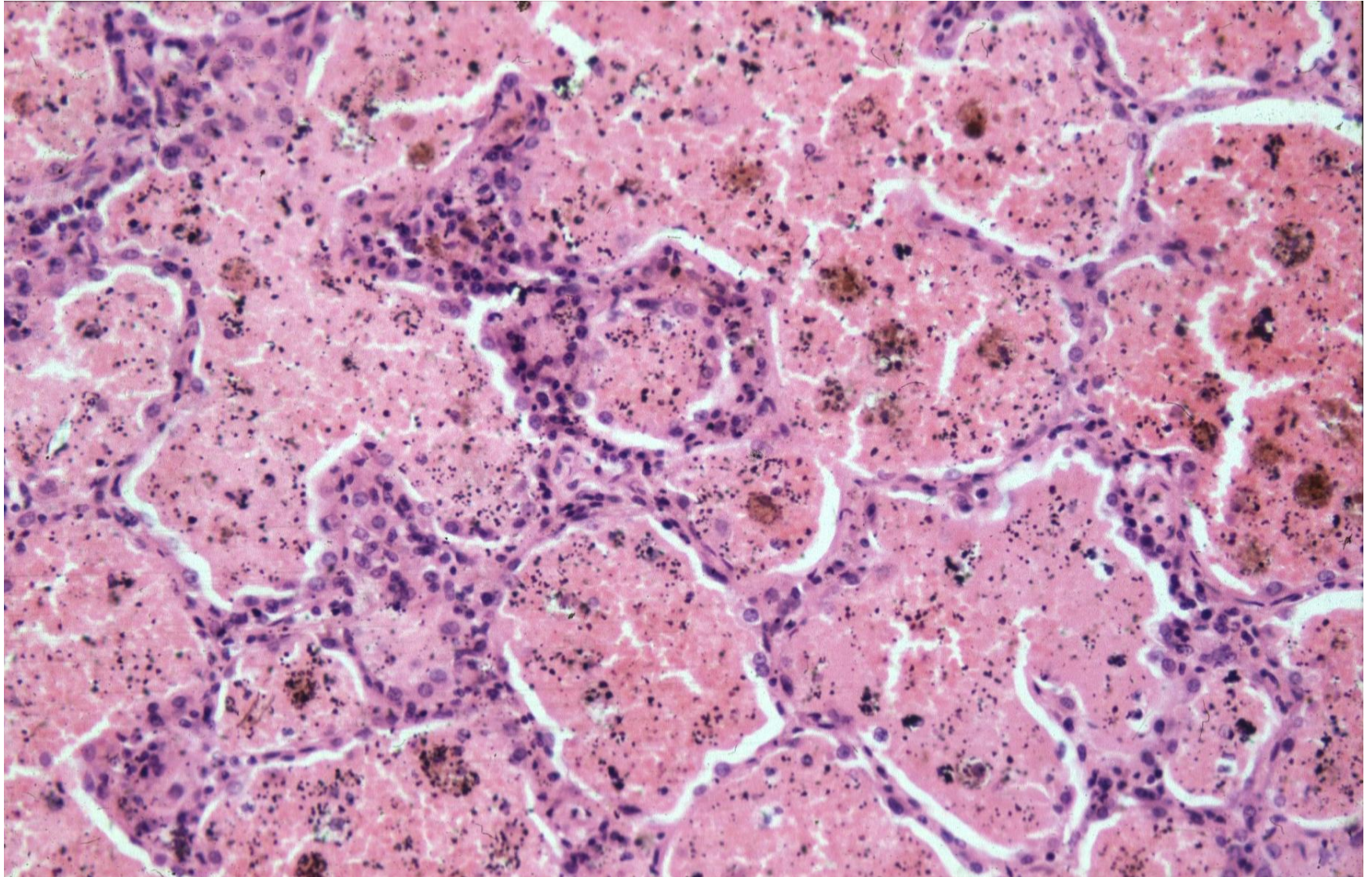
One year outcome in treated anti-GBM disease

	n	Patient survival (%)	Renal survival (%)
Creat <500	19	100	95
Creat >500	13	83	82
Dialysis	39	65	8
Total	71	77	53

Goodpasture's disease



Goodpasture's disease



Circulating anti-GBM antibodies

Negative ELISA

- Number of patients with crescentic GN and linear IgG staining but no detectable circulating Ab
- Biopsy becomes critical
- May be worth performing Western blotting

False positive ELISA

- Polyclonal B cell stimulation e.g. HCV, HIV
- May be worth performing Western blotting

Double positivity for anti-GBM ab and ANCA

- 5% of 954 ANCA+ samples anti-GBM+
- 32% of 121 anti-GBM+ samples ANCA+ (81% with anti-MPO ab)
- 68% on dialysis, 41% lung haemorrhage
- **Outcome similar to anti-GBM ab alone, but treatment variable**
- **Patients with creat <500 did well, but no dialysis dependent cases recovered RF**
- **Non renal relapses may occur**

Treatment of Goodpasture's disease

Prednisolone

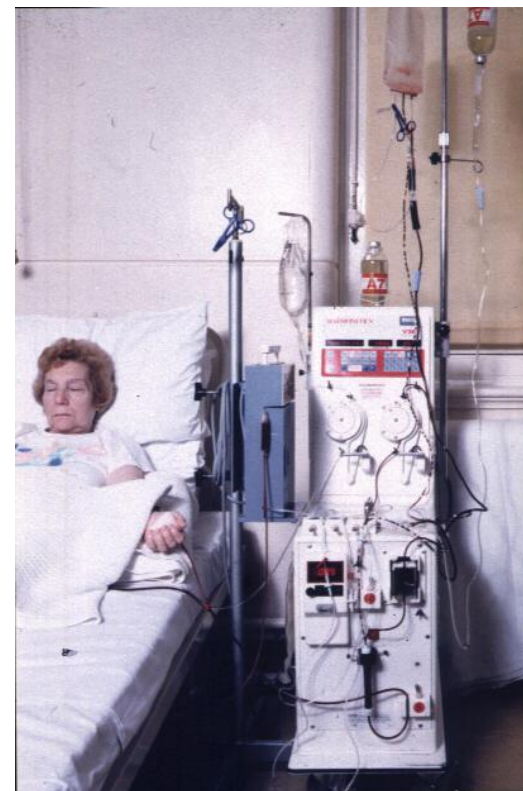1mg/kg daily (max 60mg), tapering weekly
Discontinue by 6 months

Cyclophosphamide

2mg/kg daily (adjusted for age and
renal function)
Discontinue by 3 months

Plasma exchange

60ml/kg (max 4L) for 14 days or until
anti-GBM neg
Use HSA with addition of FFP if risk
of bleeding

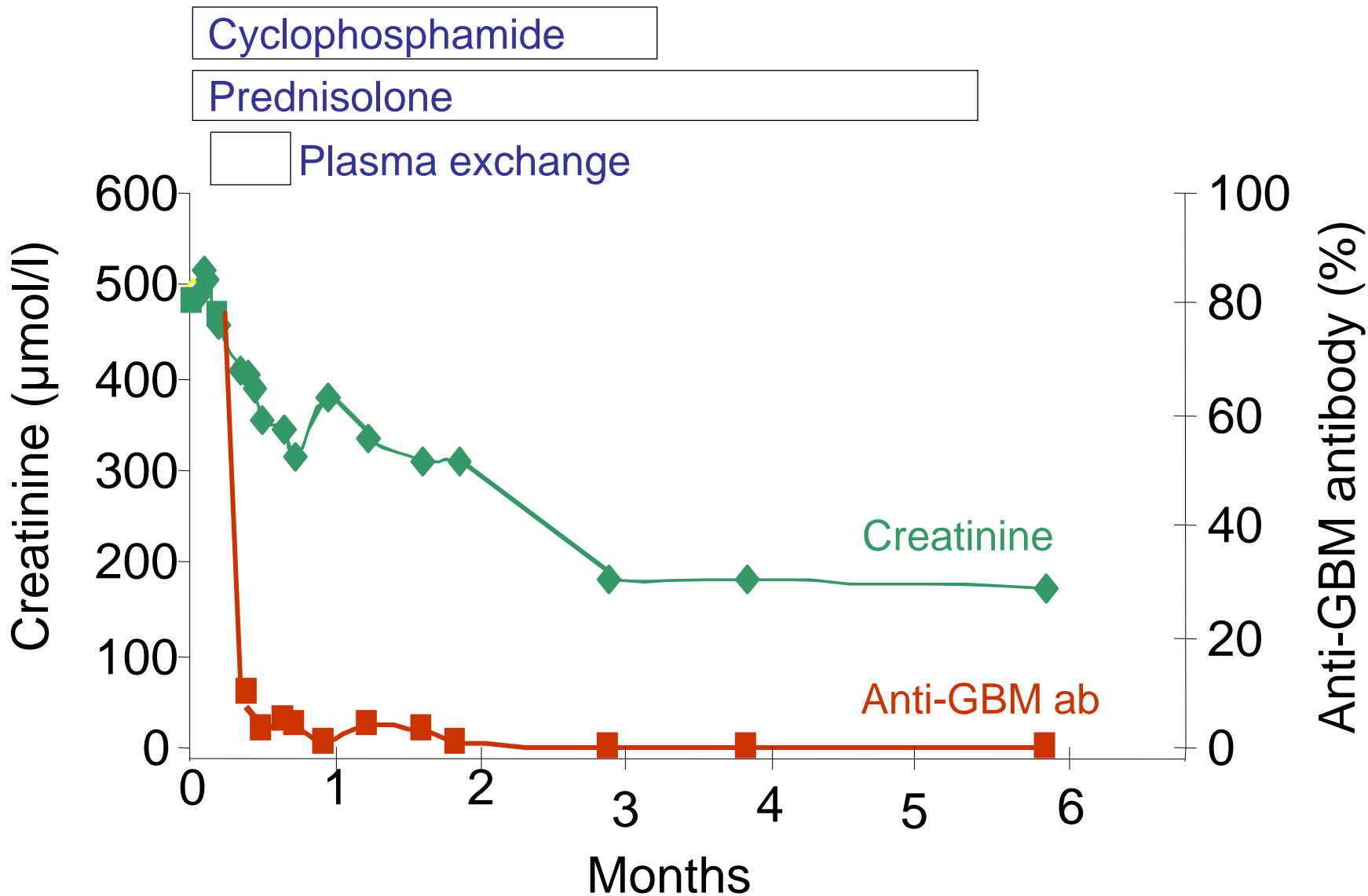


Trial of PE in anti-GBM disease

- Comparison of PE + immunosuppressive drugs vs drugs alone
- More rapid fall in anti-GBM antibody levels
- Fewer patients on dialysis (2/8 vs 6/9)
- But - less severe disease in PE group

Johnson, Medicine 1985

Effect of treatment



Future treatment

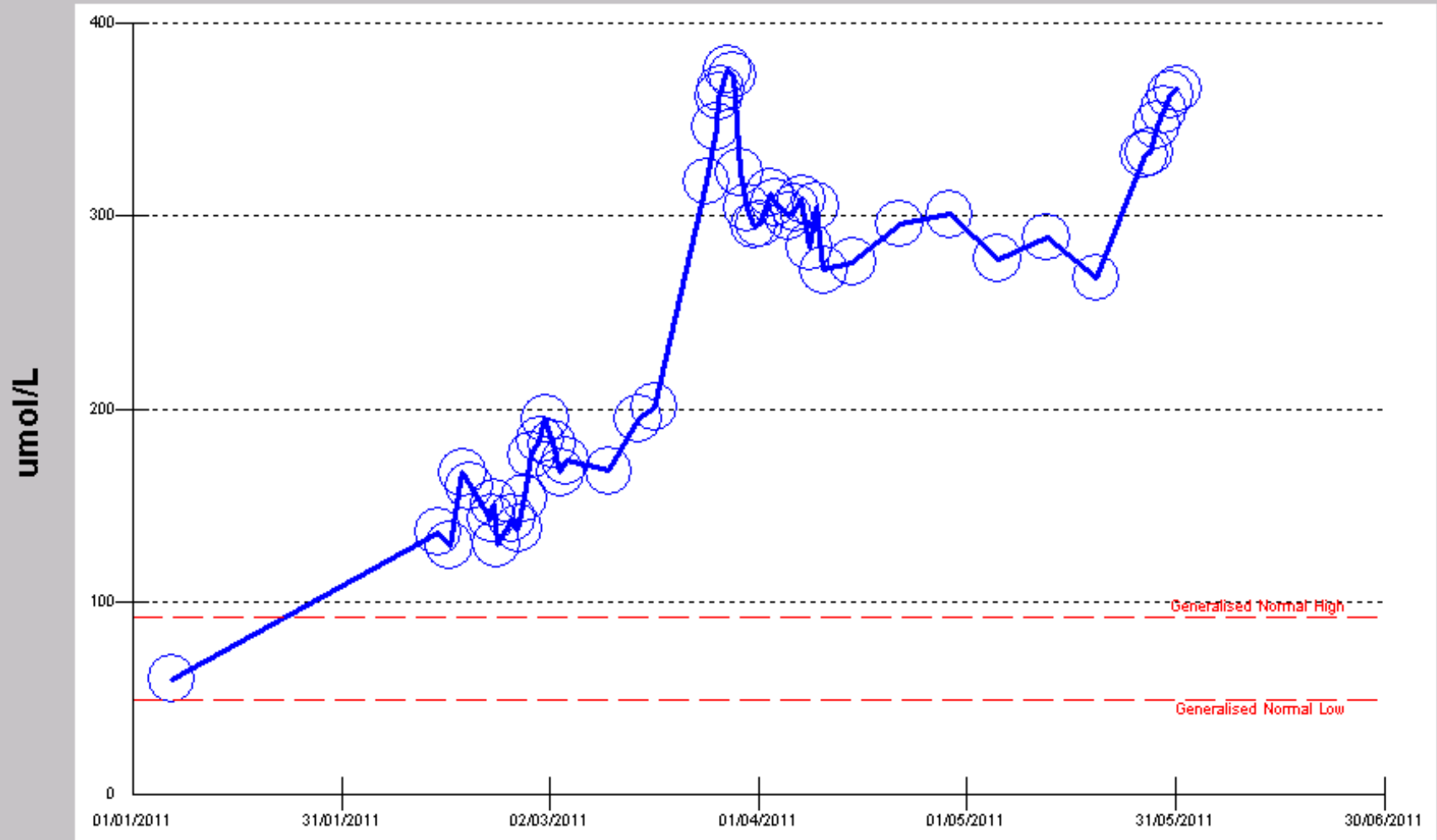
- Case reports of use of RTX, MMF, CsA in patients who are intolerant of cyclophosphamide
- Speed of onset of these agents?
- Worth treating even if on dialysis but have potential living donor as therapy accelerates anti-GBM antibody removal
- Role for RTX

Case 2

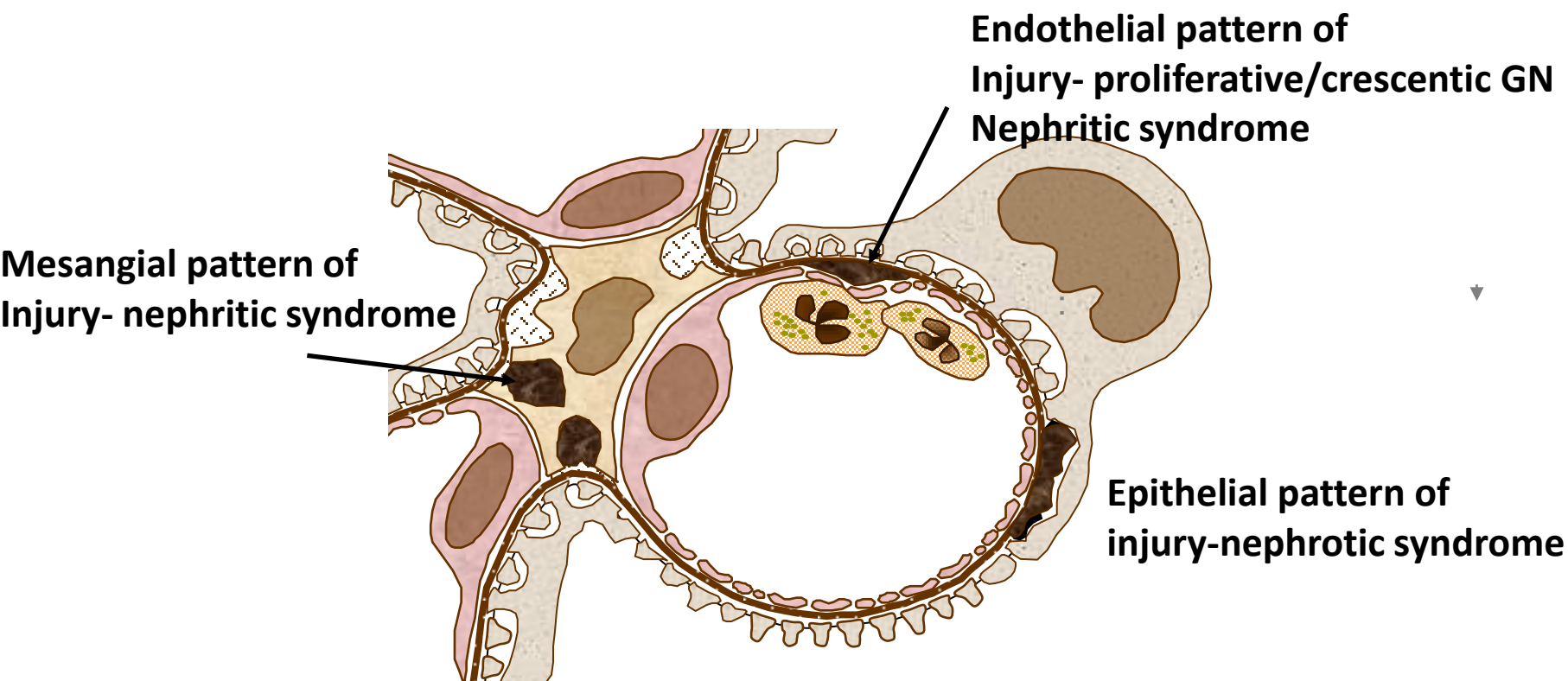
- 23 year old Turkish woman; 1 child age 3
- Diagnosed with SLE 6 months previously-arthralgias, rash; SCr 60 $\mu\text{mol/l}$
- Developed pericarditis and pleuritis started on prednisolone and azathioprine, later MMF
- Initial improvement then recurrent pericardial effusion; dsDNA ++, v. low C3/C4; negative ANCA
- Unkeen on CYP, RTX added

- Rapid decline in renal function, HT, oedema
- Admitted to poor compliance
- Eurolypus CYP 6x 500mg
- Continued decline in renal function
- Renal biopsy
- Severe crescentic glomerulonephritis with Ig deposition; ANCA /anti-GBM negative
- Increased dose of CYP, PEx x 7
- Reached end stage

Creatinine



Crescent formation in immune complex GN correlates with extent of subendothelial IC deposition



AKI in SLE

- Kidney involvement is common
 - 25-50% of patients have abnormalities of urine or renal function early in their course
 - Up to 60% of adults and 80% of children will develop renal abnormalities at some time
- Zhu et al 2011
 - 322 patients with LN; 66 with AKI (20.5 %)
 - Significant differences between groups with/without AKI

	With AKI	Without AKI
Male:female	1:2.7	1:8.8
Class III	0 %	20.7 %
Class IV	92.4 %	46.9 %
Class V	1.5 %	25.4 %
Crescents	2 (1-6)	0 (0-2)
Proteinuria g/24 hours	6.6±4.4	4.7±3.2

Eurolupus trial

n=90

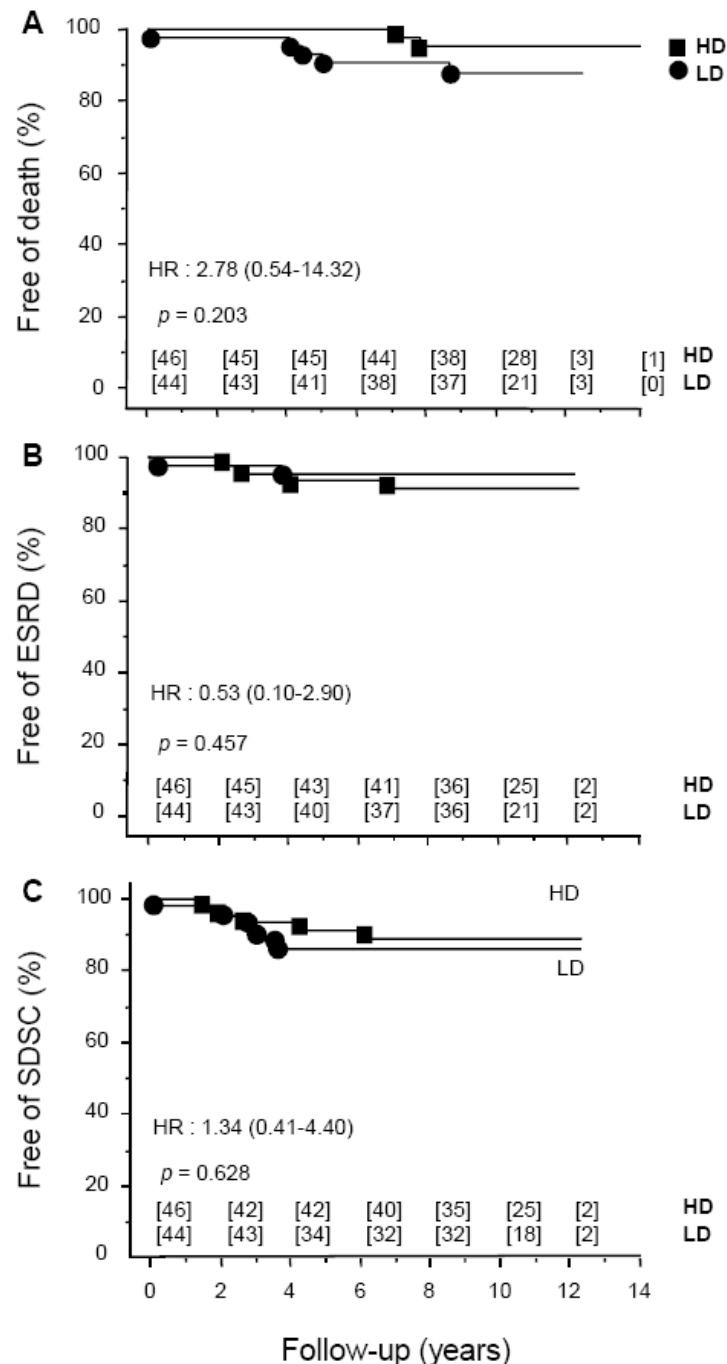
Class III and IV (83 pts) or V (7pts)

Treated: Low dose (6 x 500mg)

CYC vs High Dose (8 x 0.5g/m²) CYC

	LD	HD
ESRD	5%	9%
Doubling of SCr	14%	11%

Houssiau FA et al 2010



MMF rather than CYC in LN

- ALMS study

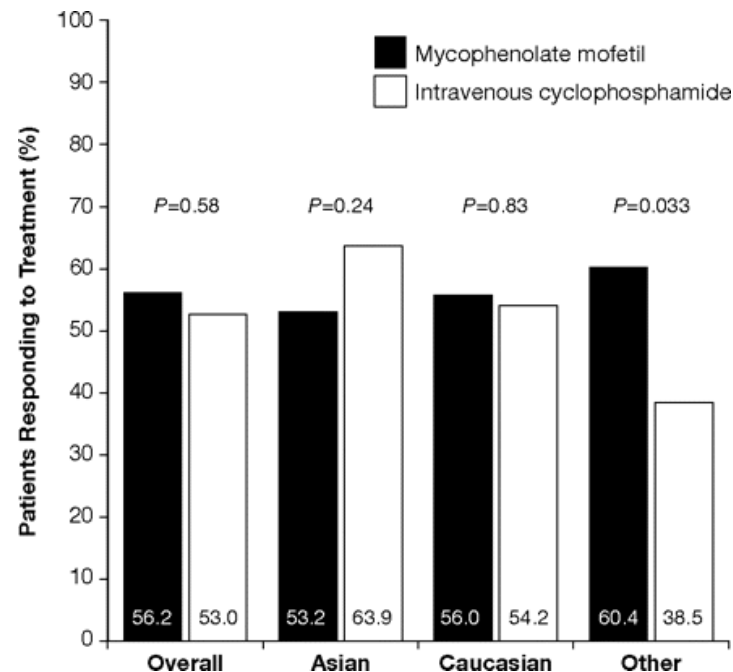
185 MMF vs 185 IVC

Median dose 2.6 g MMF v 6 doses IVC(0.75 g/m²)

Primary endpoint reduction of proteinuria and stabilisation of Scr

- 56% vs 53% reached endpoint (p=NS)

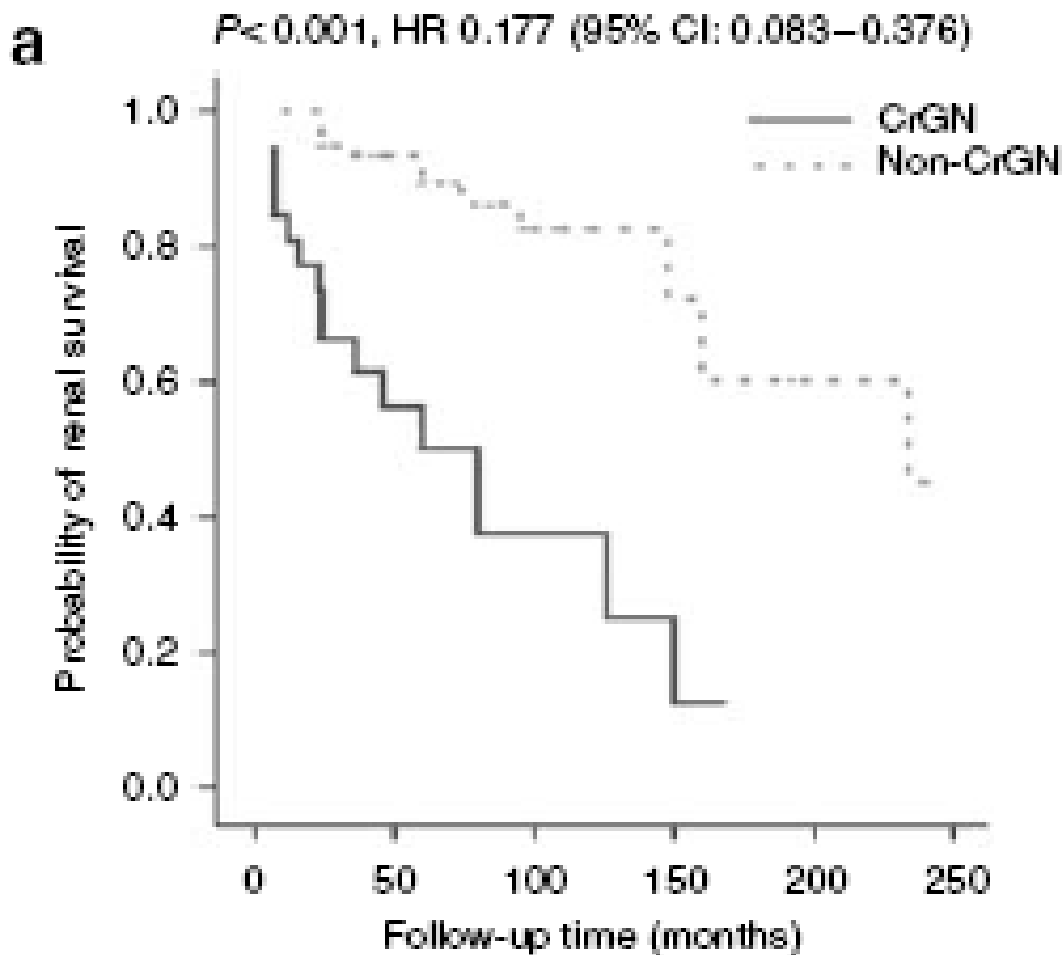
- Effect of region and ethnicity on response



SLE and crescentic nephritis

- Yu et al 2009
- 33/327 (10%) LN patients had crescentic GN
- All presented with RPGN; SCr 330 ± 235 (vs 141 ± 138)
 - All treated with MP/steroids and 6/12 CYP in 30 and MMF in 3
 - 8(24 %) CR, 16(49 %) PR, 9 (27 %)no response
 - 30% of pts had concurrent p-ANCA/anti-MPO Ab vs 2.5 % in those without crescentic nephritis
 - 1 patient had anti-GBM Ab

Outcome in crescentic LN

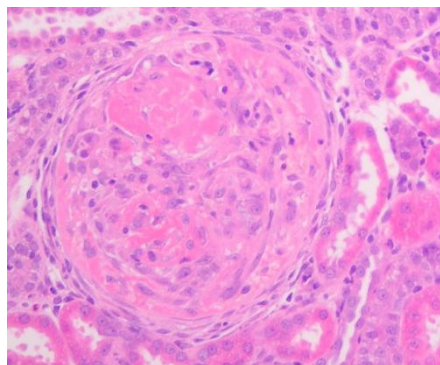
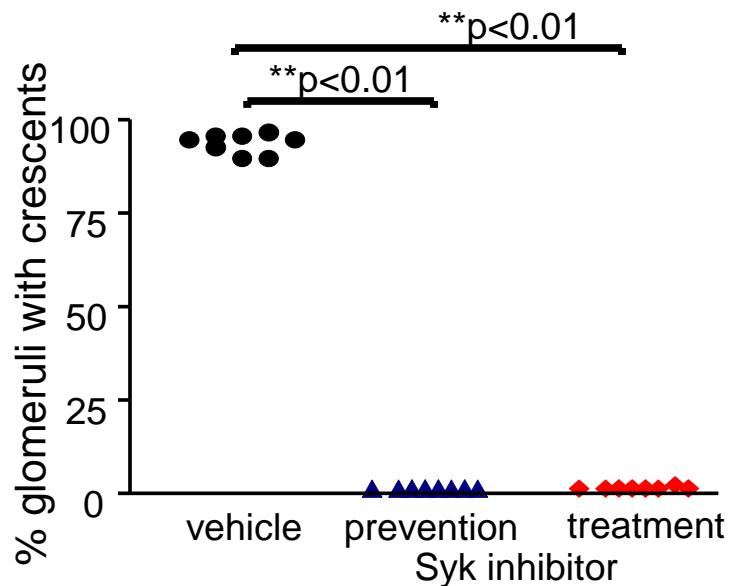


Treatment of crescentic LN

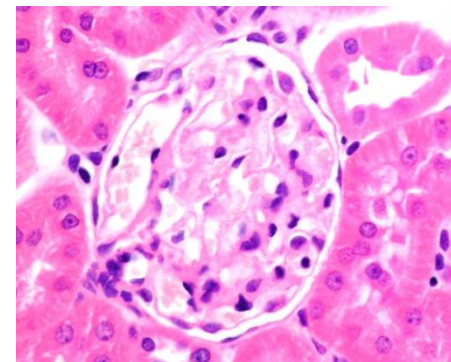
- No specific trials of RPGN or crescentic disease
- Trial of adjunctive PEx showed no benefit
 - 86 pts with LN (class III-V), excluded if SCr >530 $\mu\text{mol/l}$
- Retrospective Chinese study suggested more CR with MMF (n=27) vs CYP (n=25) treated pts (Tang 2008)

- Test for ANCA/anti-GBM
- Treatment escalation as for AAV; role for MMF ?
- Impact of non-compliance ?
- New agents ?

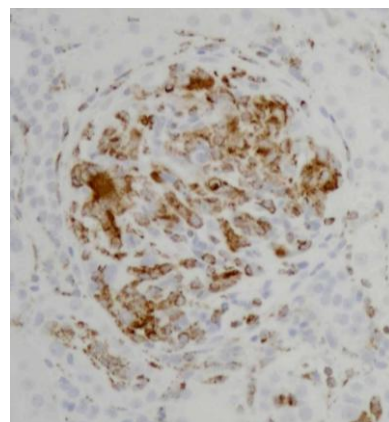
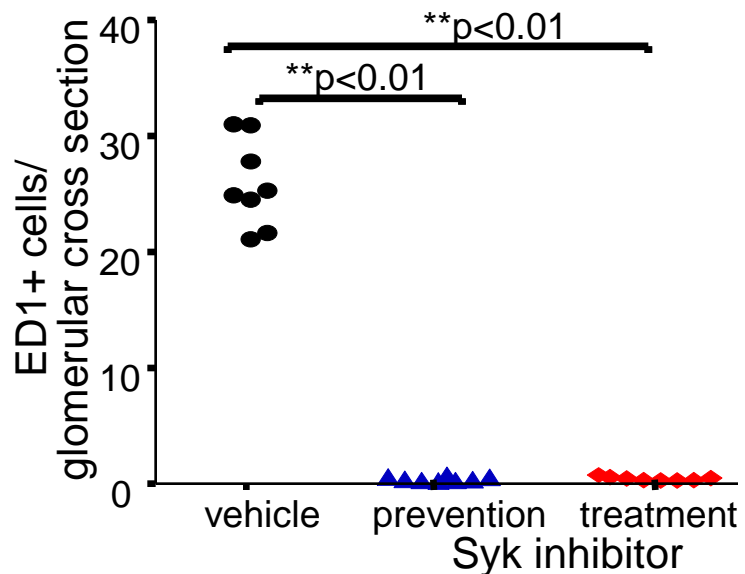
SYK inhibition in NTN



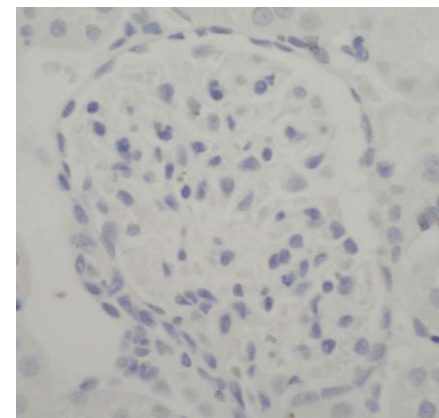
Positive control



Syk inhibitor



Positive control



Syk inhibitor

AKI in IgA

- AKI may be due to glomerular or tubular disease
- 20 pts with IgA and AKI (Wen 2010)
 - 55% crescentic GN, 55% ATN, 20% AIN
 - 7(35%) reached end stage, 11(55%) remission, 2 (10%) died

RPGN in IgA disease

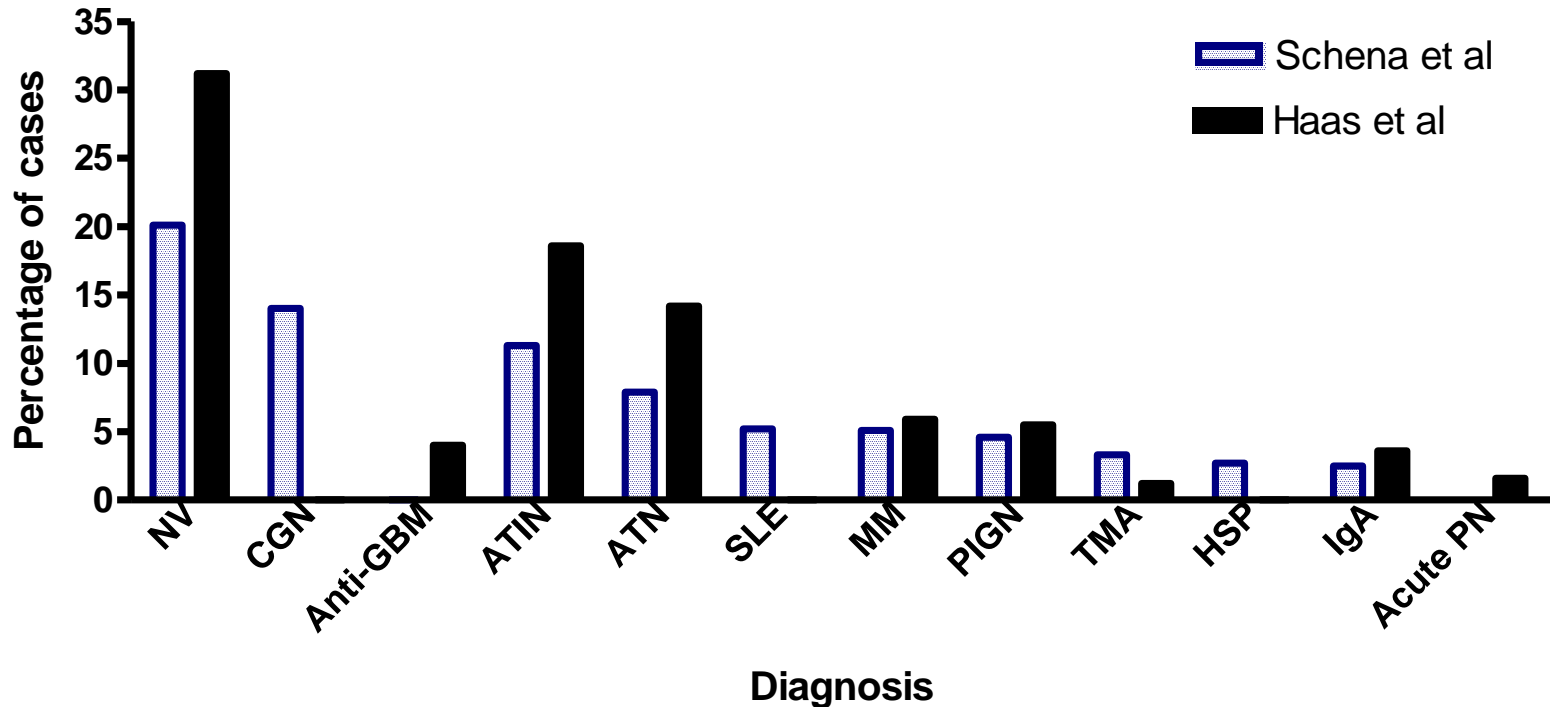
- Crescentic IgA may be characterized by HT, oedema, rapid renal function decline
- Retrospective analyses suggest benefit from steroid/CYP based regimen
- No controlled trials

Biopsy diagnoses in AKI

Patients without obvious clinical cause of ATN

Haas n=259; pts >60 years

Schena n=1273; all adult pts



Renal biopsy in the elderly

- Brown et al 2011
 - Ireland
 - 1372 native biopsies, 236 in patients >65 years(17%)
 - Commonly for AKI or nephrotic syndrome
 - Commonest diagnosis pauci immune crescentic GN
- Moutzouris et al 2009
 - USA
 - 235 patients >80 years
 - 46% for AKI; commonest diagnosis pauci immune GN (19% cases), greater than in those 60-61 yrs

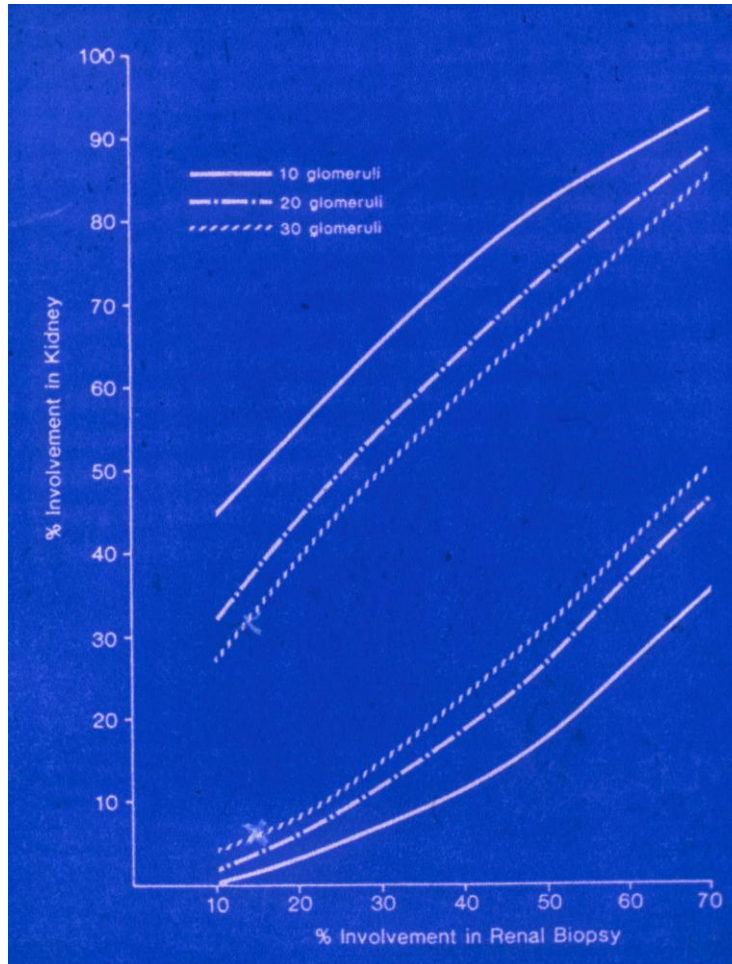
ANCA associated vasculitis

- Prolonged prodrome with extrarenal symptoms
- In small percentage may be limited to kidney (renal limited vasculitis)
- Characterized by ANCA in 90-95%
- ANCA negative disease recognised
- Crescents may be of different ages suggesting waves of inflammation
- Remember focal nature so biopsy may miss it

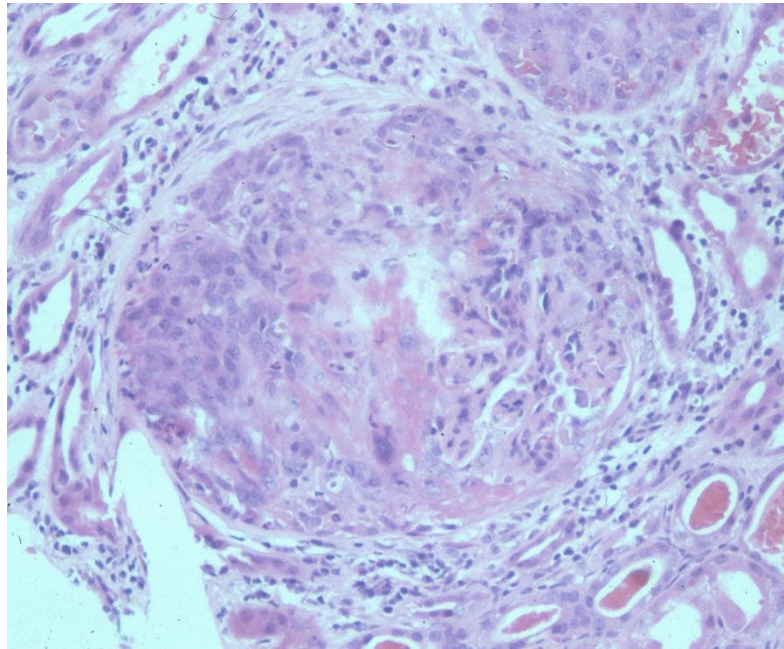
The Importance of Sample Size in the Interpretation of the Renal Biopsy

Howard L. Corwin^a, Melvin M. Schwartz^b, Edmund J. Lewis^a

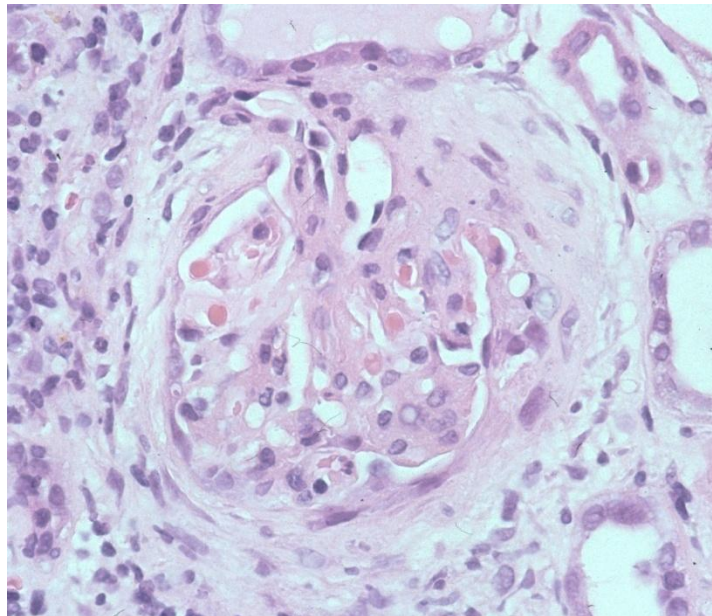
Section of Nephrology, ^aDepartment of Medicine and ^bDepartment of Pathology, Rush-Presbyterian-St. Luke's Medical Center, Chicago, Ill., USA



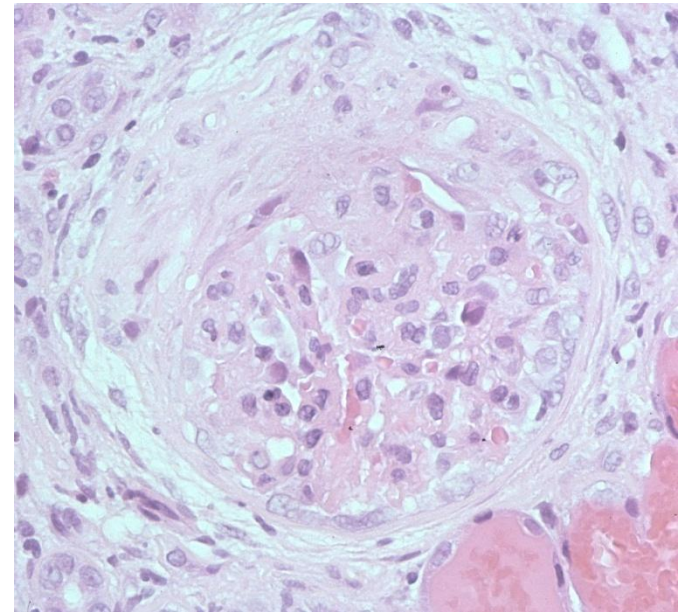
A biopsy sample of 20 glomeruli is necessary to exclude mild focal disease



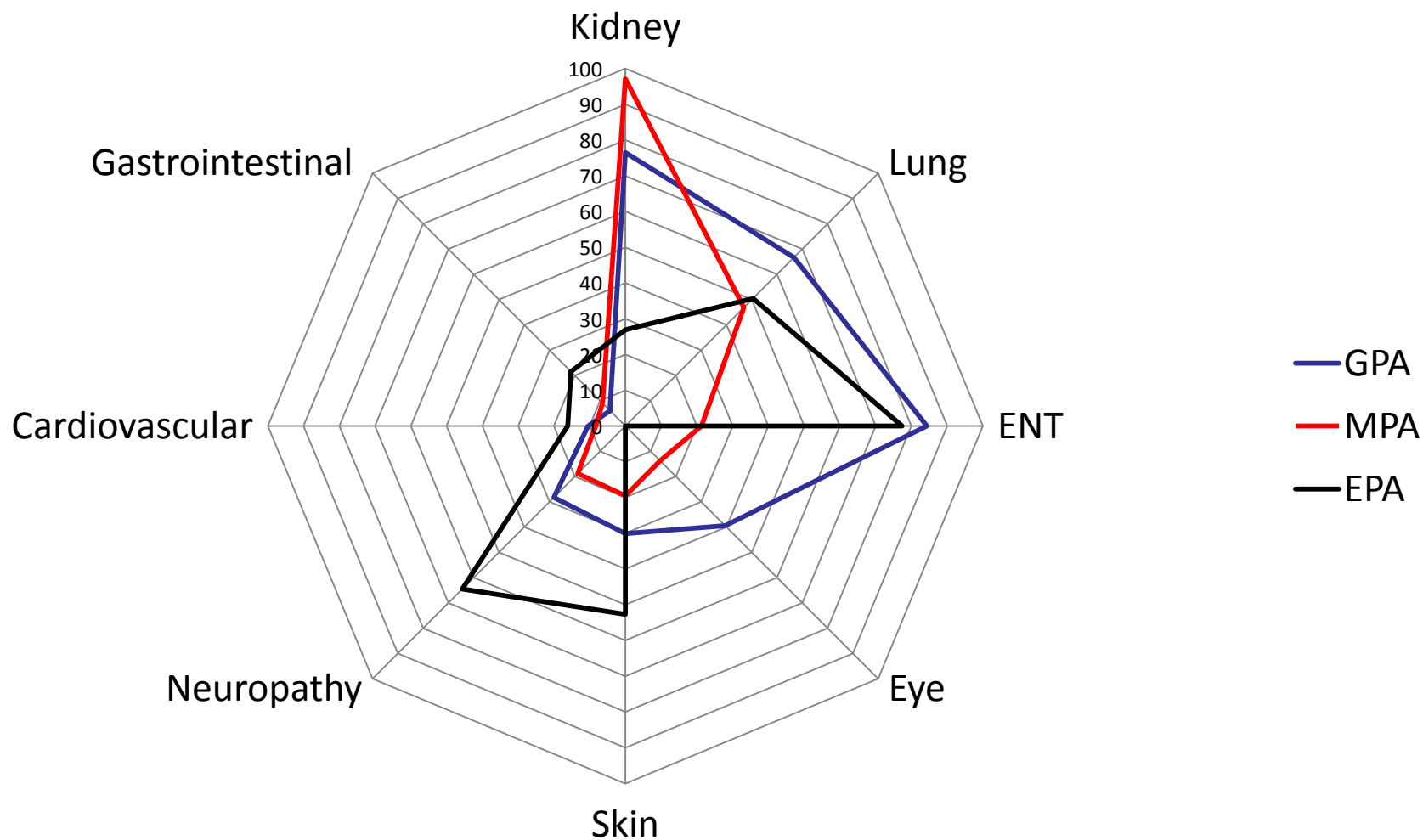
Cellular
crescent



Fibrous
Crescents



Presenting symptoms of AAV



Adapted from Mahr et al 2012 and sinico 2005

Renal involvement in AAV

Outcome of ANCA-Associated Renal Vasculitis: A 5-Year Retrospective Study

Anthony D. Booth, MD, Mike K. Almond, MD, Aine Burns, MD, Peter Ellis, MA, Gill Gaskin, MD,
Guy H. Neild, MD, Martin Plaisance, MD, Charles D. Pusey, MD, and David R.W. Jayne, MD,
for the Pan-Thames Renal Research Group

N= 246 patients with AAV and renal involvement
MPA 49%, GPA 33%, Renal limited 13.5%, CSS 4.5%
Mean Serum creatinine 342mmol/l
ANCA 92%

1 year survival 82%

5 year survival 76%

Mortality increased with : age>60, SCr>200, ESRD and sepsis

ESRD in 28% of which 47% died

ANCA associated vasculitis

- Recovery of dialysis dependent renal failure in up to 60% patients
- Treatment regimens with steroids, cyclophosphamide/RTX, plasmapheresis
- High morbidity and mortality from treatment
- Rituximab in recent clinical trials is efficacious but not better with regards adverse effects

Rapidly Progressive Glomerulonephritis

- Causes variable
- May have other systemic manifestations of disease
 - Arthralgia, rash, ENT disease, etc
- May be renal limited
- May have serological tests that are positive, but..
 - 10% of pauci-immune crescentic GN is ANCA negative
 - Rare patients have anti-GBM disease without circulating anti-GBM antibodies
 - Other unusual variants eg IgA-ANCA, anti-GBM to other alpha 3(IV) chains
 - Not all laboratory tests equally sensitive

Rapidly Progressive Glomerulonephritis

- Think of this as potential diagnosis
- Dipstick and microscope urine
- Rapid laboratory tests- don't send as routine; pick up phone
- Early biopsy
- Empirical treatment maybe warranted- but discuss with others first

Conclusions

- RPGN common cause of AKI
- Timely diagnosis required to maximise renal recovery
- Treatment regimens still associated with significant morbidity
- New strategies are required to improve short and long term outcome